



REPUBLIC OF TURKEY
MARMARA UNIVERSITY
HEALTH OF SCIENCES INSTITUTE

**EVALUATION OF INDEX SYSTEMS MEASURING GINGIVAL
OVERGROWTH**

Dt. AHMAD SAFA ALKATEB
MASTER OF SCIENCE

DEPARTMENT OF PERIODONTOLOGY

MENTOR
Prof. Dr. LEYLA KURU

2019 - İSTANBUL

THESIS APPROVAL

THESIS APPROVAL FORM

Institute : Marmara University Institute of Health Sciences
Programme : Master of Science (MSc.)
Department : Periodontology
Owner of the Thesis : Ahmad Safa ALKATEB
Exam Date & Time : 25.09.2019. 10:00 AM
Title of the Thesis : Evaluation of Index Systems Measuring Gingival Overgrowth.

This study has been approved as a MSc. Thesis in regard to content and quality.

	Title, Name-Surname (Affiliation)	Signature
Supervisor	Prof. Dr. Leyla KURU Marmara University	
Member	Dr. Öğr. Üyesi. Hafize ÖZTÜRK ÖZENER Marmara University	
Member	Doç. Dr. Hare GÜROSY Yeditepe University	

APPROVAL

This thesis has been deemed by the aforementioned jury in accordance with the relevant articles of "Marmara University Graduate Education and Examination Regulations" and has been approved by Administrative Board of Institute with decision dated ..02.10.2019..... and numbered54.....


Prof. Dr. Feyza ARICIOĞLU
Director of Institute of Health Sciences

I. STATEMENT

Hereby I declare that this thesis study is my own study, I had no unethical behavior in all stages from planning of the thesis until writing thereof, I obtained all the information in this thesis in academic and ethical rules, I provided reference to all of the information and comments which could not be obtained by this thesis study and took these references into the reference list and had no behavior of breaching patent rights and copyright infringement during the study and writing of this thesis.

Dt. Ahmad Safa Alkateb

Signature

A handwritten signature in purple ink, appearing to read 'Ahmad Safa Alkateb', written in a cursive style.

II. ACKNOWLEDGEMENT

I would first like to express my special thanks of gratitude to my supervisor Prof. Dr. Leyla KURU, who expertly guided me through my post-graduate program and who shared the excitement through all years of reasearch. Her unwavering enthusiasm for work kept me constantly engaged with my thesis, and her personal generosity helped me gain a lot during my residency at the department. It was a great privilege and honor to work and study under your guidance hocam.

I would also like to thank Dr. Öğr. Üye. Hafize ÖZTÜRK ÖZENER for her support in each step to achieve this study and make this thesis completed. All thanks for her encouragement and trust during my academic studies at the department.

I have been privileged to experience how passionate teachers can make a difference. I am grateful to my lecturers Prof. Dr. Başak DOĞAN, Dr. Öğr. Üye. Kemal Naci KÖSE, Dr. Öğr. Üye. Selin YILDIRIM, and Dr. Öğr. Üye. Ömer Birkan AĞRALI.

No words ever can describe family. I am very grateful for the warmth and support of you, my father Prof. Dr. Beshir Alkateb, my mother Samar Hassibi, and my sister Dima Alkateb. Thank you for encouraging me in all of my persuits and inspiring me to achieve higher steps. I will be always grateful for all kind of limitless support, constant encouragement, and untiring efforts you have dedicated for me. Nothing would have been possible without us standing next to each other.

To the one who believed that long distances could not be a matter ever, but rather strengthening us together more. To the one who shared with me five years of everything. Thank you Hala MANSOUR.

Friendship is something really precious, and people who hold on are friends for a lifetime. I would like to thank Mohamad ALIMAM, Leen ALTOUNJI, Faisal

KAYALI, and Bader MOKRESH for sharing with me the journey from Aleppo to Istanbul.

I am so grateful and thankful to Mnire ARIKOL and MAHIR ARIKOL for being next to me step by step during the years I have spent in Turkey. Words are not enough to describe how much a person is blessed when he is away from his hometown, but still surrounded by family.

I owe a debt of gratitude to my dearest colleagues Dt. Onur EROĐLU, Dt. Mustafa SAYED IESSA, Dt. Mmin alık, and Dt. Ece YETİŐ for being always there as roommates, great fellows, and true friends.

III. CONTENTS	Page No
I. STATEMENT	I
II. ACKNOWLEDGEMENT	II
III. CONTENTS	IV
IV. ABBREVIATIONS AND SYMBOLS	X
V. LIST OF PICTURES	XI
VI. LIST OF FIGURES	XIII
VII. LIST OF TABLES	XIV
1. ÖZET	1
2. SUMMARY	2
3. INTRODUCTION AND AIM	3
4. GENERAL INFORMATION	5
4.1. Preface	5
4.2. Types of Gingival Overgrowth	5
4.2.1. Inflammatory gingival overgrowth	7
4.2.1.1. Acute inflammatory gingival overgrowth	7
4.2.1.2. Chronic inflammatory gingival overgrowth	8

4.2.2. Drug-induced gingival overgrowth	10
4.2.2.1. Phenytoin-induced gingival overgrowth	12
4.2.2.2. Cyclosporine-induced gingival overgrowth	16
4.2.2.3. Calcium channel blockers-induced gingival overgrowth	20
4.2.3. Enlargements associated with systemic diseases	22
4.2.3.1. Conditioned gingival overgrowth	22
4.2.3.1.1. Gingival overgrowth in vitamin C deficiency	23
4.2.3.1.2. Gingival overgrowth in pregnancy	23
4.2.3.1.2.1. Marginal gingival overgrowth in pregnancy	23
4.2.3.1.2.2. Tumor-like gingival overgrowth in pregnancy	24
4.2.3.1.3. Gingival overgrowth in puberty	25
4.2.3.1.4. Plasma cell gingivitis	26
4.2.3.2. Systemic diseases that cause gingival overgrowth	26
4.2.3.2.1. Wegener's granulomatosis	26
4.2.3.2.2. Sarcoidosis	26
4.2.3.2.3. Leukemia	26
4.2.4. Idiopathic gingival overgrowth	27
4.2.5. Neoplastic enlargement	28
4.2.5.1. Benign tumors	28

4.2.5.2. Malignant tumors	28
4.2.6. Hereditary gingival fibromatosis	29
4.3. Treatment of Gingival Overgrowth	29
4.3.1. Treatment of chronic inflammatory gingival overgrowth	30
4.3.2. Treatment of drug-induced gingival overgrowth	30
4.3.3. Treatment of gingival overgrowth during pregnancy	32
4.3.4. Treatment of gingival overgrowth during puberty	32
4.4. Gingival Overgrowth Indices	32
4.4.1. Intra oral measurements	33
4.4.1.1. Kimball index	33
4.4.1.2. Frankel index	34
4.4.1.3. Robinson index	34
4.4.1.4. Harris and Ewalt index	34
4.4.1.5. Aas index	36
4.4.1.6. Angelopoulos and Goaz index	36
4.4.1.7. Conard et al. index	37
4.4.1.8. Addy et al. index	38
4.4.1.9. Daley et al. index	38
4.4.1.10. McGaw et al. index	39

4.4.1.11. Kitamura et al. index	39
4.4.1.12. Pernu et al. index	41
4.4.1.13. Miller and Damm index	42
4.4.1.14. Somacarrera et al. index	43
4.4.1.15. Nery et al. index	43
4.4.1.16. Prasad et al. index	44
4.4.1.17. Inglés et al. index	49
4.4.2. Plaster model measurements	53
4.4.2.1. Ingle et al. index	53
4.4.2.2. Seymour et al. index	54
4.4.2.3. Dahllöf et al index	56
4.4.2.4. King et al. index	56
4.4.3. Intra-oral photographs measurements	59
4.4.3.1. Heijl and Sundin index	59
4.4.3.2. O'valle et al. index	60
4.4.3.3. Ellis et al. index	61
5. MATERIALS AND METHODS	63
5.1. Patient Selection	63
5.2. Study Design	64

5.3. Gingival Overgrowth Measurements	64
5.3.1. Modified Harris and Ewalt index	64
5.3.2. Seymour et al. index	65
5.3.3. Hyperplastic index by King et al.	67
5.3.4. Ellis et al. index	69
5.4. Statistical Analysis	70
5.5. Calibration	71
6. RESULTS	72
6.1. Demographic Data	72
6.2. Gingival Overgrowth Indices	73
6.2.1. Intra-examiner reliability	73
6.2.1.1. Modified Harris and Ewalt index	73
6.2.1.2. Seymour et al. index	77
6.2.1.3. King et al. index	81
6.2.1.4. Ellis et al. index	85
6.2.2. Inter-examiner reliability	86
6.2.2.1. Modified Harris and Ewalt index	86
6.2.2.2. Seymour et al. index	90
6.2.2.3. King et al. index	94

6.2.2.4. Ellis et al. index	98
7. DISCUSSION	100
8. CONCLUSION	108
9. REFERENCES	109
10. ENCLOSURES	125
En 1. Ethical Committee Descision Form	125
En 2. Informed Consent Form	126
En 3. Consent Form	128
En 4. Patient's Card	129
En 5. Gingival Overgrowth Measuremet Card	130
11. CURRICULUM VITAE	131

IV. ABBREVIATIONS AND SYMBOLS

C.C.B.	: Calcium channel blocker
CCN2	: Cellular communication network factor 2
C.N.S.	: Central nervous system
CsA	: Cyclosporine A
D.B.	: Dişeti büyümesi
DO	: Disto-oral
DV	: Disto-vestibule
G.S.I.	: Gingival size index
G.O.	: Gingival overgrowth
H.G.F.	: Hereditary gingival fibromatosis
H.I.	: Hyperplastic index
IL	: Interleukin
K	: Kappa
Kg	: Kilogram
MO	: Mesio-oral
MV	: Mesio-vestibule
µg	: Microgram
mg	: Milligram
ml	: Millileter
mm	: Millimeter
ng	: Nanogram
O	: Oral
PMN	: Polymorphonuclear
TGF-β	: Transforming growth factor beta
V	: Vestibule

V. LIST OF PICTURES

Picture 4.1. Clinical view of phenytoin-induced G.O.

Picture 4.2. Clinical view of CsA-induced G.O.

Picture 4.3. Clinical view of nifedipine-induced G.O.

Picture 4.4. Clinical view of G.O. in pregnant woman

Picture 4.5. Clinical view of pubertal G.O.

Picture 4.6. Clinical view of an Epulis

Picture 4.7. Clinical view of H.G.F.

Picture 4.8. Classification of G.O. by (Angelopoulos and Goaz)

Picture 4.9. Group A in Kitamura et al. study

Picture 4.10. Group B in Kitamura et al. study

Picture 4.11. Group C in Kitamura et al. study

Picture 4.12. Group D in Kitamura et al. study

Picture 4.13. Classification of G.O. by pernu et al.

Picture 4.14. Grade 3 of G.O. index by Nery et al.

Picture 4.15. Grade 0 and 1 G.O. according to modified Harris and Ewalt index

Picture 4.16. Grade 2 G.O. according to modified Harris and Ewalt index

Picture 4.17. Grade 3 G.O. according to modified Harris and Ewalt index

Picture 4.18. Grade 4 and 5 G.O. according to modified Harris and Ewalt index

Picture 4.19. Study model, showing the three points of measurements according to Ingle et al.

Picture 4.20. Study model, showing the three points of measurements according to Ingle et al.

Picture 4.21. Example of intermittent tooth eruption in 60 days according to Ingle et al.

Picture 4.22. Occlusal view of the upper anterior section of the study model

Picture 4.23. Study model shows buccal surfaces of the upper and lower anterior teeth

Picture 4.24. Classification of G.O. by Heijl and Sundin

Picture 5.1. Assessing the horizontal aspect by H.I. of King et al.

Picture 5.2. Intra-oral photograph of the buccal aspect of a drug-induced G.O. patient

VI. LIST OF FIGURES

Figure 4.1. Relationship among inflammation, fibrosis, and drugs which cause G.O. in humans

Figure 4.2. Gingival units for recording probing depth of gingival sulcus and G.O. according to modified Harris and Ewalt index

Figure 4.3. Grade 0 G.O. according to Inglés et al.

Figure 4.4. Grade 1 G.O. according to Inglés et al.

Figure 4.5. Grade 2 G.O. according to Inglés et al.

Figure 4.6. Grade 3 G.O. according to Inglés et al.

Figure 4.7. Grade 4 G.O. according to Inglés et al.

Figure 4.8. Horizontal component (thickening) to assess G.O. by Seymour et al. index

Figure 4.9. Vertical component (encroachment) to assess G.O. by Seymour et al. index

Figure 4.10. Criteria to assess G.O. according to Ellis et al. index

Figure 5.1. Vertical component of the Seymour et al. index

Figure 5.2. The degree of G.O. according to Ellis et al. index

VII. LIST OF TABLES

Table 4.1. Classification of G.O. according to the etiopathogenesis.

Table 4.2. Classification of G.O. according to the location.

Table 4.3. Classification of G.O. by Kimball.

Table 4.4. Classification of G.O. by Robinson.

Table 4.5. Classification of G.O by Harris and Ewalt.

Table 4.6. Classification of G.O. by Angelopoulos and Goaz.

Table 4.7. Classification of G.O. by Addy et al.

Table 4.8. Classification of G.O. by McGaw et al.

Table 4.9. Classification of G.O. by Pernu et al.

Table 4.10. Classification of G.O. by Miller and Damm.

Table 4.11. Classification of G.O by Nery et al. in dentate subjects.

Table 4.12. Classification of G.O. by Nery et al. in edentulous patients.

Table 4.13. Classification of G.O by Prasad et al. (Modified Harris and Ewalt).

Table 4.14. Classification of G.O. horizontally by Seymour et al.

Table 4.15. The H.I of horizontal component or labio-lingual direction by King et al.

Table 4.16. The HI of vertical component or apico-coronal direction by King et al.

Table 4.17. Classification of gingival overgrowth by O'valle et al.

Table 4.18. Classification of G.O. by Ellis et al.

Table 5.1. Classification of G.O according to the modified Harris and Ewalt index.

Table 5.2. Classification of G.O. horizontally according to the Seymour et al. index.

Table 5.3. The horizontal component of H.I. index by King et al.

Table 5.4. The vertical component of H.I. index by King et al.

Table 5.5. Classification of G.O. according to Ellis et al. index.

Table 6.1 . Demographic data of all participants.

Table 6.2. Reliability of Examiner-1 measuring modified Harris and Ewalt index.

Table 6.3. Reliability of Examiner-2 measuring modified Harris and Ewalt index.

Table 6.4. Reliability of Examiner-3 measuring modified Harris and Ewalt index.

Table 6.5.a. Reliability of Examiner-1 measuring vertical component of Seymour et al. index.

Table 6.5.b. Reliability of Examiner-1 measuring horizontal component of Seymour et al. index.

Table 6.6.a. Reliability of Examiner-2 measuring vertical component of Seymour et al. index.

Table 6.6.b. Reliability of Examiner-2 measuring horizontal component of Seymour et al. index.

Table 6.7.a. Reliability of Examiner-3 measuring vertical component of Seymour et al. index.

Table 6.7.b. Reliability of Examiner-3 measuring horizontal component of Seymour et al. index.

Table 6.8.a. Reliability of Examiner-1 measuring vertical component of King et al. index.

Table 6.8.b. Reliability of Examiner-1 measuring horizontal component of King et al. index.

Table 6.9.a. Reliability of Examiner-2 measuring vertical component of King et al. index.

Table 6.9.b. Reliability of Examiner-2 measuring horizontal component of King et al. index.

Table 6.10.a. Reliability of Examiner-3 measuring vertical component of King et al. index.

Table 6.10.b. Reliability of Examiner-3 measuring horizontal component of King et al. index.

Table 6.11. Reliability of Examiner-1 measuring Ellis et al. index.

Table 6.12. Reliability of Examiner-2 measuring Ellis et al. index.

Table 6.13. Reliability of Examiner-3 measuring Ellis et al. index.

Table 6.14. Reliability of Examiner-1-2 measuring modified Harris and Ewalt index.

Table 6.15. Reliability of Examiner-1-3 measuring modified Harris and Ewalt index.

Table 6.16. Reliability of Examiner-2-3 measuring modified Harris and Ewalt index.

Table 6.17.a. Reliability of Examiner-1 and Examiner-2 measuring vertical component of Seymour et al. index.

Table 6.17.b. Reliability of Examiner-1 and Examiner-2 measuring horizontal component of Seymour et al. index.

Table 6.18.a. Reliability of Examiner-1 and Examiner-3 measuring vertical component of Seymour et al. index.

Table 6.18.b. Reliability of Examiner-1 and Examiner-3 measuring horizontal component of Seymour et al. index.

Table 6.19.a. Reliability of Examiner-2 and Examiner-3 measuring vertical component of Seymour et al. index.

Table 6.19.b. Reliability of Examiner-2 and Examiner-3 measuring horizontal component of Seymour et al. index.

Table 6.20.a. Reliability of Examiner-1 and Examiner-2 measuring vertical component of King et al. index.

Table 6.20.b. Reliability of Examiner-1 and Examiner-2 measuring horizontal component of King et al. index.

Table 6.21.a. Reliability of Examiner-1 and Examiner-3 measuring vertical component of King et al. index.

Table 6.21.b. Reliability of Examiner-1 and Examiner-3 measuring horizontal component of King et al. index.

Table 6.22.a. Reliability of Examiner-2 and Examiner-3 measuring vertical component of King et al. index.

Table 6.22.b. Reliability of Examiner-2 and Examiner-3 measuring horizontal component of King et al. index.

Table 6.23. Reliability of Examiner-1 and Examiner-2 measuring Ellis et al. index.

Table 6.24. Reliability of Examiner-1 and Examiner-3 measuring Ellis et al. index.

Table 6.25. Reliability of Examiner-2 and Examiner-3 measuring Ellis et al. index.

Dişeti Büyümesini Ölçen İndeks Sistemlerinin Değerlendirilmesi

Öğrencinin adı: Ahmad Safa ALKATEB

Danışman: Prof. Dr. Leyla KURU

1. ÖZET

Giriş ve Amaç: Bu çalışmanın amacı dişeti büyümesini (D.B.) ölçen dört indeksin uyumluluğunu analiz etmek ve DB'nin tanısı için güvenilirliklerini karşılaştırmak ve şiddet derecesini saptamaktır.

Gereç ve Yöntem: Generalize enflamatuvar veya ilaca bağlı D.B. görülen 30 hastanın alçı modelleri ve fotoğraf kayıtları değerlendirildi. Bu çalışmaya dahil edilen hastaların 12 anterior dişlerinin olması koşulu arandı. Ölçümler 3 araştırmacı tarafından, alçı modeller için modifiye Harris ve Ewalt indeksi, Seymour ve ark. indeksi ve King ve ark. indeksine göre yapıldı. Ellis ve Seymour indeksini değerlendirmek için ağız içi fotoğraflar kullanıldı. Kayıtlı ölçümlerin araştırmacının kendi içi ve araştırmacılar arası güvenilirliğine uygunluğu, her bir indeks için ağırlıklı kappa kullanılarak gerçekleştirildi.

Bulgular: Modifiye Harris ve Ewalt indeksi, araştırmacının kendi içi toplam kappa değerlerini 0,428-0,783 ve araştırmacılar arası toplam kappa değerlerini 0,042-0,071 arasında gösterdi. Seymour ve ark. indeksi sırasıyla araştırmacının kendi içi toplam kappa değerlerini sırasıyla 0,512-0,823 ile 0,724-0,876 arasında dikey olarak ve yatay olarak, araştırmacılar arası toplam kappa değerlerini sırasıyla 0,235-0,279 ile 0,255-0,626 arasında dikey ve yatay olarak göstermiştir. King ve ark. indeksi sırasıyla, 0,653-0,855 ve 0,587-0,868 arasında dikey ve yatay olarak araştırmacının kendi içi toplam kappa, dikey olarak ve yatay olarak sırasıyla araştırmacılar arası toplam kappa değerlerini, sırasıyla 0,372-0,635 ile 0,393-0,595 arasında göstermiştir. Ellis ve ark. indeksi en yüksek araştırmacının kendi içi sonuçları 0,758-0,855, ve araştırmacılar arası toplam kappa değerleri 0,716-0,804 arasındadır.

Sonuç: Ellis ve ark. indeksi, bu klinik olgunun şiddetini tespit etmek amacıyla en yüksek tekrarlanabilirliği olan D.B. ölçümü için güvenilir ve uygulanabilir olarak kabul edilir.

Anahtar kelimeler: Dişeti büyümesi, İndeks, İnflamasyon, Fotoğraf, Sınıflandırma.

Evaluation of Index Systems Measuring Gingival Overgrowth

Student name: Ahmad Safa ALKATEB

Mentor: Prof. Dr. Leyla KURU

2. SUMMARY

Objective: The aim of this study was to assess the concordance of four gingival overgrowth indices to check their reliability for successful means of diagnosis and treatment.

Material and Methods: A total of 30 subjects who have generalized gingival overgrowth were included in our study. Plaster models and photographic records of these patients were analyzed. Twelve anterior teeth are required for including patients in this study. Three examiners performed measurements on plaster models for modified Harris and Ewalt index, Seymour et al. index, and King et al. index. Intraoral photographs were used to assess Ellis et al. index. Concordance of intra-examiner and inter-examiner reliability of the recorded measurements was carried out for each index using weighted kappa (*K*).

Results: Modified Harris and Ewalt index showed intra-examiner total kappa values between 0,428-0,783 and inter-examiner total kappa values between 0,042-0,071. Seymour et al. index revealed intra-examiner total kappa values between 0,512-0,823, and 0,724-0,876 vertically and horizontally, respectively, and inter-examiner total kappa values between 0,235-0,279, and 0,255-0,626 vertically and horizontally, respectively. King et al. index presented intra-examiner total kappa values between 0,653-0,855, and 0,587-0,868 vertically and horizontally, respectively, and inter-examiner total kappa values between 0,372-0,635 and 0,393-0,595 vertically and horizontally, respectively. Ellis et al. index achieved the highest intra-examiner results with total kappa values between 0,758-0,855, and inter-examiner total kappa values between 0,716-0,804.

Conclusion: Ellis et al. index is considered reliable and applicable for measuring G.O. with the greatest reproducibility for detecting severity of this clinical phenomenon.

Key words: Gingival overgrowth, Index, Inflammation, Photograph, Classification.

3. INTRODUCTION AND AIM

Gingival overgrowth (G.O.) is an alteration in gingival morphology that might be accompanied with diverse factors, and characterized by vertical and horizontal enlargement of the gingival tissues in both gingivo-incisal and bucco-lingual directions respectively (Miranda et al., 2012).

The types of G.O. are generally classified as inflammatory, drug-induced, enlargements associated with systemic diseases, neoplastic G.O. and hereditary overgrowth (Carranza et al., 2015).

Various mechanisms have been described by the investigators in the etiopathogenesis of G.O. In inflammatory G.O., the microorganisms produce certain toxic substances which cause damage to the epithelium and connective tissue along with intercellular components. In this process, the polymorphonuclear (PMN) leukocytes cause cytotoxic alterations in fibroblasts and decrease the production of collagen (Shukla et al., 2014).

On the other hand, it is a frequent side effect associated with three major drug groups: anticonvulsants, calcium channel blocker (C.C.B.), and immunosuppressants especially cyclosporin A (CsA) (Malek et al., 2019). Dental plaque causes G.O. too and appears to cause a secondary inflammation when it is associated with drug-induced G.O. (Carranza et al., 2015).

The prevalence of drug-induced G.O. varies between drugs, and its expression is influenced by a variety of risk factors (Malek et al., 2019). This prevalence ranges between 6 to 15% for nifedipine, about 50% for phenytoin, and between 25% to 30% in adult patients and >70% in children when it is accompanied by CsA (Malek et al., 2019). Moreover, according to a recent data of Hatahira et al. (Hatahira et al., 2017), the reported ratio of CsA-induced G.O. is 39,4.

A vast range of indices have been employed to set the severity of G.O. which has produced doubt and uncertainty with regard to this clinical manifestation (Miranda-Ruis et al., 2012). The wide variability in results noticed between studies which used

different methods (vertical / horizontal G.O. indices) might be the result of using non credible indices during the measurement process (Miranda-Ruis J et al., 2012). For example, Hassell (Hassell et al., 1984) presented in his literature which reviews the oral manifestations in epileptic patients under phenytoin therapy, the wide variation in the incidence of G.O. that ranges from 0% to 100% (Blair, 1939; Grob and Herold, 1972).

The criteria to assess clinically G.O. is not universally defined. Therefore, it may be inappropriate to compare the results of the incidence of G.O. reported in various studies (King et al., 1993). Therefore, difficulties in the interpretation of these reports are in large part due to the differences in the criteria used to assess the lesion (Barclay et al., 1992).

Many of the clinical investigations are case reports of patients with G.O. with no index used to quantify the hyperplasia of the gingiva (Rateitschak-plüss et al., 1983; Bennett and Christian, 1985), while other studies have relied on semi-quantitative indices that involve a significant subjective component in the assessment of G.O. (Tyldesley and Rotter, 1984; McGaw et al., 1987).

The treatment, diagnosis, prevention of recurrence of G.O. could be achieved when the clinician is able to realize the size of G.O. including its horizontal and vertical components as well as the extent and severity's relation with the etiopathogenesis. The perfect methodology to assess G.O. is with the help of a proper and suitable G.O. index (Miranda et al., 2012).

Some G.O. indices are considered invasive since they demand many measurements, or even a data-processing system. On the other hand, other G.O. indices are less convenient and considered as complex and expensive (Miranda et al., 2012).

Therefore, the main objective of this study is to anatomize the concordance of four G.O. indices in order to compare their reliability and reproducibility for an early and accurate diagnosis of G.O.

4. GENERAL INFORMATION

4.1. Preface

The term G.O. is the gingival intensification and proliferation which is a prevailing character of the diseased gingival tissues (Carranza et al., 2015). In other words, nowadays, in the clinical aspect, it is much more appropriate to clinicians to use “gingival enlargement” as a term when the histological confirmation is absent (Payne et al., 2001).

The gingiva and the surrounding periodontal soft tissues might enlarge due to different interactions between the host and the environment (Hallmon and Rossmann, 1999). Therefore, G.O. can be classified according to the pathogenesis and location of occurrence (Carranza et al., 2015).

4.2. Types of Gingival Overgrowth

Due to the varied presentations of G.O., the diagnosis and categorization are based on the etiopathogenesis, location, size, extent, *etc.* (Agrawal and Arvind, 2015). There still could be some lesions which may present in an unusual manner and make the diagnosis challenging (Agrawal and Arvind, 2015). By knowing the existence of common and rare presentations of G.O., one can keep a broad view when formulating a differential diagnosis of localized (isolated, discrete, regional) or generalized G.O. (Agrawal and Arvind, 2015). Various mechanisms have been discovered by the investigators in the etiopathogenesis of G.O. Therefore, G.O. can be classified according to the pathogenesis and location of occurrence as it is presented in Table 4.1 and, Table 4.2, respectively.

Table 4.1. Classification of G.O. according to the etiopathogenesis (Carranza et al., 2015).

Type	Description
Inflammatory	Acute
	Chronic
Drug-induced	Anticonvulsants
	Immunosuppressants
	Calcium channel blockers
Conditioned overgrowth	Pregnancy
	Puberty
	Vitamin C deficiency
	Plasma cell gingivitis
	Nonspecific conditioned enlargement (Pyogenic granuloma)
Systemic diseases that cause gingival overgrowth	Leukemia
	Granulomatous diseases (e.g., Wegener's granulomatosis, Sarcoidosis)
Neoplastic overgrowth (gingival tumors)	Benign tumors
	Malignant tumors
Hereditary gingival fibromatosis (HGF)	Various degrees of attached gingival hyperplasia

Table 4.2. Classification of G.O. according to the location (Carranza et al., 2015).

Type	Description
Localized	Limited to the gingiva adjacent to a single tooth, or group of teeth
Generalized	Involving the gingiva throughout the mouth
Marginal	Confining the marginal gingiva
Papillary	Confining the attached gingiva
Diffuse	Involving marginal and attached gingiva and papillae
Discrete	An isolated sessile or a pedunculated, tumorlike enlargement

4.2.1. Inflammatory gingival overgrowth

Inflammatory G.O. can be both acute and chronic (Carranza et al., 2015).

4.2.1.1. Acute inflammatory gingival overgrowth

Gingival abscess

Generally, the gingival abscess occurs on the marginal gingiva or interdental papillae with a sudden onset. It is a painful and localized lesion expanding rapidly. The lesion usually turns to fluctuant and pointed within 1-2 days. Furthermore, a purulent exudate might be expressed from a surface orifice. When a foreign material is forcefully inserted into the gingiva, bacteria are carried deep into the gingival tissues causing gingival abscess (Carranza et al., 2012).

The lesion ruptures spontaneously when it is left to progression (Carranza et al., 2015).

Lateral (periodontal) abscess

Lateral abscesses include the periodontium and produce G.O. and may occur in the following ways (Carranza et al., 2015).

- When the inflammatory process extends laterally from the inner surface of the periodontal pocket into the connective tissue of the pocket wall. Formation of the abscess occurs when drainage into the pocket space is impaired.
- When the infection extends from the periodontal pocket deeply into the supporting periodontal tissues and the suppurative inflammation localizes on the lateral aspect of the root.
- When tooth has been exposed to trauma or when the lateral wall of the root is perforated during endodontic therapy, a periodontal abscess might present in the absence of periodontal disease.
- When calculus is remained after incomplete treatment of periodontal pocket, the gingival wall shrinks, thereby occluding the pocket orifice, and a periodontal abscess occurs in the sealed-off portion of the pocket.
- Formation in a pocket with a tortuous course around the root. A periodontal abscess may form in the cul-de-sac, the deep end of which is shut off from the surface.

4.2.1.2. Chronic inflammatory gingival overgrowth

Chronic inflammatory G.O. can be localized or generalized. Clinically, it appears as a slight ballooning of the interdental papillae and marginal gingiva. It produces a “life-preserver-shaped bulge” around the involved teeth in its early stages. This “life-preserver-shaped bulge” can increase in size until covering part of the clinical crowns (Carranza et al, 2015). The progression is slow and painless, unless there is a complication with any kind of acute infection or trauma (Carranza et al, 2015). Chronic

inflammatory G.O. occurs as a discrete sessile or a pedunculated mass that looks alike tumor. It can be located in the interproximal, marginal or attached gingiva. As mentioned above, these lesions grow slowly, but may undergo a spontaneous reduction in size that is followed by exacerbation and continued overgrowth (Carranza et al, 2015). Painful ulceration occurs in the area between the enlarged mass and the adjacent gingiva.

Prolonged stimulation by dental plaque cause idiopathic G.O. Other factors may play role in plaque accumulation and retention such as irritation by anatomic abnormalities, inappropriate orthodontic and restorative appliances, and mainly poor oral hygiene (Hirschfeld, 1932).

Gingivitis and G.O. are frequently encountered in patients with mouth-breathing habit. The anterior maxilla is the common site of occurrence. The exposed surface of the gingiva appears to be reddish and edematous with a diffuse surface shininess (Carranza et al, 2015). In addition, the altered gingival tissues in many cases are clearly demarcated from the neighboring unexposed gingiva (Carranza et al, 2015). The exact mechanism in which mouth breathing affects the gingival tissues is not clearly defined, but it is generally referred to irritation from dehydration of the exposed surface. However, comparable alterations in gingival tissues could not be achieved by using “air drying” in the experimental animals’ gingival tissues (Maier, 1949).

The microorganisms produce certain toxic substances like collagenases, hyaluronidase, chondroitin sulphate, protease, etc., which cause damage to epithelium and connective tissue along with intercellular components leading to widening of small capillaries and venules with formation of capillary loops between rete pegs. In this process, PMN leukocytes undergo diapedesis and emigration and thus cause cytotoxic alterations in fibroblasts and decrease the production of collagen (Carranza et al, 2015).

4.2.2. Drug-induced gingival overgrowth

The G.O. is a consequence after administration of some drugs including anticonvulsants, immunosuppressants, or C.C.B. It is associated with disfiguring and disproportionate overgrowth of the gingival tissues after administration of selected drugs which have generated an attention regarding this clinical manifestation in the scientific community (Hallmon and Rossmann, 1999). It is one of the most frequent and troublesome side effects and an adverse reaction of the above mentioned medications (Hallmon and Rossmann, 1999).

The condition may cause mastication, speech, tooth eruption and aesthetic complications. Clinically and microscopically, the symptoms of the G.O. caused by various types of drugs are similar to each other (Butler et al., 1987; Rees, 1998).

Clinically, the overgrowth of the gingiva begins painlessly in the interdental papilla as a beadlike overgrowth that then extends to both buccal and lingual gingival margins. As the progression continues, a massive tissue fold that encroaches parts of the anatomical clinical crown is developed as a result of uniting between the marginal and papillary overgrowths. This fold eventually creates complications in occlusion (Carranza et al, 2015). When G.O. condition is not accompanied by a secondary inflammatory complication, the lesion is firm, resilient, pinky color, mulberry shaped, with a lobulated surface and no inclination to bleed. The overgrowth starts projecting from beneath the gingival margin, with a linear groove separating between the margin and the enlargement. In such cases, applying plaque control protocols becomes difficult due to the presence of the overgrowth caused by the drug leading into a secondary inflammatory process (Carranza et al, 2015). The resulted enlargement in these cases when the drug-induced G.O. is accompanied with an inflammatory process will not only add to the size of the lesion originally caused by the drug but will also produce a red or bluish-red discoloration, increase the bleeding, and efface the demarcations on the lobulated surface. (Carranza et al, 2015).

Drug-induced G.O. is usually generalized all over the mouth, but it occurs to be much more severe in both maxillary and mandibular anterior regions. The overgrowth

appears in dentulous regions where teeth are still present, and disappears in edentulous areas where teeth have been extracted. Reports of mucosal hyperplasia in edentulous mouths are rare but have been mentioned in literature (Dallas, 1963; Dreyer and Thomas, 1978).

Drug-induced G.O. might present in mouths with no plaque, and it might be absent in patients with plentiful deposits of plaque (Hallmon and Rossmann, 1999). Some investigators agree that the inflammatory process is a precondition for developing overgrowth of the gingiva, which could be stopped by perfect oral hygiene and plaque removal (Ciancio et al., 1972; Nuki and Cooper, 1972).

Using toothbrush or chlorhexidine toothpaste to control oral hygiene (Russell and Bay, 1978) reduces the inflammation, but does not have influence on the G.O.

Fibroblasts are less active in non-inflammatory conditions and have no response in patients under phenytoin therapy. On the other hand, fibroblasts within inflammation are active as the result of inflammatory mediators and the endogenous growth factors (Hussell, 1982; Hussell and Page, 1978).

Microscopically, human G.O. lesions' regarding its cellular and tissue features caused by different drugs, have different manifestations (Trackman and Kantarci, 2015). Analyzing human gingivectomy samples provided evidence that the cellular and tissue characteristics differ depending on the type of treatment drug. The most fibrotic G.O. lesions are the ones induced by phenytoin. On the other hand, G.O. lesions induced by CsA. have an increased inflammation and present little fibrosis. Nifedipine-induced G.O. are mixed (Trackman and Kantarci, 2015).

Findings were based on histological and histomorphometric analysis. Expression in phenytoin-induced G.O. of transforming growth factor beta (T.G.F- β) and cellular communication network factor 2 (C.C.N. 2) which is also known as connective tissue growth factor and induce extracellular matrix synthesis and accumulation, was elevated as it is shown in Figure 4.1. Mesenchymal cell proliferation was increased in tissues which exhibited G.O., while apoptosis was diminished, especially in

phenytoin-induced G.O. (Hong et al., 1999; Uzel et al., 2001; Kantarci et al., 2007; Thompson et al., 2007).

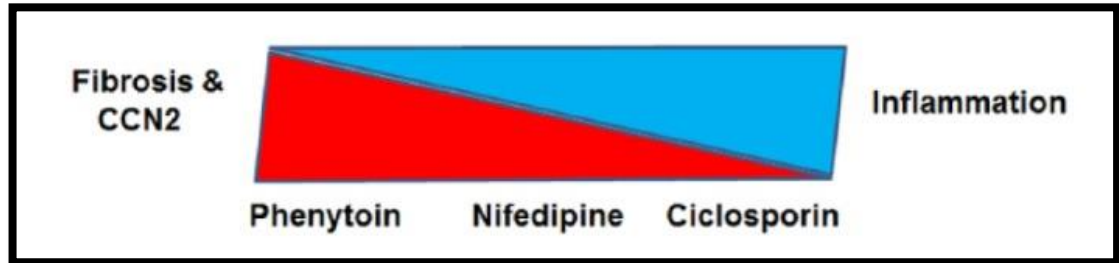


Figure 4.1. Relationship among inflammation, fibrosis, and drugs which cause G.O. in humans (Trackman and Kantarci, 2015).

4.2.2.1. Phenytoin-induced gingival overgrowth

A genetic willingness is suspected for determining the susceptibility of developing G.O. in patients treated with phenytoin (Hassell et al., 1978; Raeste et al., 1978).

Epilepsy has been historically considered as an ancient disease for which a lot of treatment methodologies and remedies have been hailed (Robinson, 1942). In May 1937, Merritt and Putnam (Merritt and Putnam, 1938) introduced sodium diphenyl hydantoinate as an anticonvulsant drug. They were first to determine its efficiency towards electrically introduced convulsions in animals, and then apply it clinically in epileptic patients and report the results in September 1938 (Merritt and Putnam, 1938). The Council on Pharmacy and Chemistry of the American Medical Association adopted the name “phenytoin sodium” on the drug (Council on pharmacy and chemistry, 1941). The drug is derived from glycolyl urea instead of malonyl urea which results in common toxic reactions to both of them such as nystagamus, tremor, aggressiveness, irritability, stupor, psychotic episodes and coma (over dosages) (Robinson, 1942). On the other hand, the adverse and toxic reactions related to phenytoin sodium solely are diplopia, ocular pain, vomiting, nervousness, anorexia and G.O. They stated that children were more susceptible to gingival changes and less often young adults, and presented in gingival areas where teeth were still existed and no other gingival pathology presented (Robinson, 1942). Structurally, it is similar to

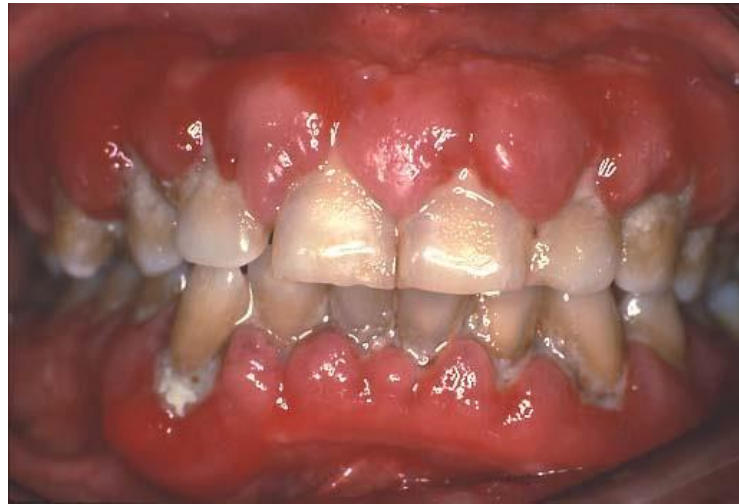barbiturates with a white crystalline bitter powder (Robinson, 1942). The drug is considered as soluble in water, slightly soluble in alcohol, and insoluble in benzene and ether (Council on pharmacy and chemistry, 1941). Phenytoin decreases the motor cortex of the central nervous system (C.N.S.) by settling down the neuronal discharge and restricting the neuronal excitation by blocking calcium influx through cell membranes (Leppik, 1990; Seymour and Heasman, 1988; Wilson and Kornman, 2019).

Phenytoin-induced G.O. is identified as a discrete pathological presence for years (Kimball, 1939) and is usually found as a diverse effect of phenytoin. The incidence range of phenytoin-induced G.O. is from 0% to 84.5% with an average effect around 50% (Angelopoulos and Goaz, 1972; Angelopoulos, 1975; Penarrocha-Diago et al., 1990). Angelopoulos and Goaz declared that the existence of a rational explanation for this major variation is reasonable, and even though a lot of investigators have tried to clarify this dilemma, most will agree that a satisfactory and pleasant explanation of this variation is still absent (Angelopoulos and Goaz, 1972).

Although a number of studies have stated that the presence of phenytoin-induced G.O. is related to daily dose, duration of usage and blood or salivary levels of phenytoin (Addy et al., 1983; Livingston, 1970), several studies did not find any correlation between phenytoin-induced G.O. and these factors (Dahllöt and Modéer, 1986; Hassell and Hefti, 1991; Thomason et al., 1992). The prevalence of overgrowth in gingival tissues has been observed to be much higher in children and institutionalized people (Dahllöt and Modéer, 1986; Stinnett et al., 1987).

The enlargement of the interdental papillae in phenytoin-induced G.O. (Picture 4.1.) is accompanied, and it is less frequently encountered with increasing thickness of the gingival marginal tissues (Penarrocha-Diago et al., 1990). The enlarged interdental papillae extends buccally and/or lingually, beclouding the gingival tissues and tooth surfaces (Hallmon and Rossmann, 1999). When the affected interdental papillae enlarge to the extent that they are connected, pseudoclefts are clinically presented. In other words, pseudoclefts result from the overlapping of adjacent marginal gingiva and papillary confluence. As the coronal progression of the

enlarged gingival tissues might partially or totally obscure the clinical crowns, conversely, the enlarged gingival tissues diminish when it approximates the mucogingival junction (Penarrocha-Diago et al., 1990).



Picture 4.1. Clinical view of phenytoin-induced G.O.

The incidence of phenytoin-induced G.O. in edentulous patients is considered to be rare. Nevertheless, it has been observed in some cases and under pontics of fixed partial dentures (Royer et al., 1983).

In addition, there are reports of phenytoin-induced G.O. preceded the eruption of primary teeth, which eventually resulted in delayed eruption of the teeth (Shafer, 1961; Vernillo and Schwartz, 1987).

Conard et al. (Conard et al., 1974) stated that many theories have been suggested to explain G.O. as a side effect of the phenytoin drug. However, none of the suggested mechanisms has yet explained this clinical phenomenon satisfactorily. On the other hand, nor of the proposed mechanisms have explained why are the gingival tissues only affected. The pathogenesis of phenytoin-induced G.O. is still not clear. A lot of *in vitro* studies were dedicated for investigating phenytoin's effect on human gingival fibroblasts in tissue culture (Angelopoulos and Goaz, 1972; Hassell, 1981; Hassell et al., 1976).

In comparison with non-phenytoin control patients, the optimal cell growth's rate is two times more than occurred at the control group (Hassell, 1981).

5-para-hydroxyphenyl-5-phenylhydantoin is the major metabolite of phenytoin and presents 50-75% of the daily dosage (Hassell, 1981). The minor presence of phenytoin's metabolites is 3-O-methyl-catechol which modifies the behavior of cells *in vitro* without affecting cellular proliferation unlike 5-para-hydroxyphenyl-5-phenylhydantoin which caused G.O. in animal model (Raeste et al., 1978).

Other observations backup the concept that fibroblasts' phenytoin-sensitive subpopulations are predetermined genetically (Stinnett et al., 1987; Johnson et al., 1990; Ballard and Butler, 1974; Dallhof et al., 1991).

It was found that fibroblasts from phenytoin-induced G.O. produce greater collagen and protein when compared to normal gingival controls (Johnson et al., 1990). The synthesis of fibroblasts, in an age dependent, decrease in normal gingiva. On the other hand, these changes were not observed in the phenytoin-gingival tissues, suggesting that they might represent a unique phenotype (Johnson et al., 1990).

In 1985, Seymour et al. (Seymour et al., 1985) studied the effects of phenytoin and sodium valproate on the periodontal health in adult epileptic patients by comparing a test group (n=30) of patients under the treatment of both medications with a control group (n=15) of healthy periodontal patients. Comparison between the sodium valproate group and the control group showed no significant differences of the parameters assessed. The percentage of the G.O. turned out to be higher in epileptic patients treated with phenytoin than patients in both under sodium valproate treatment and periodontally healthy.

Tissues taken from phenytoin-induced G.O. have increased glycosaminoglycan compared with gingival tissues from normal control patients (Ballard and Butler, 1974; Dahllof et al., 1991; Dahllof et al., 1984). Phenytoin's effect on glycosaminoglycan synthesis in fibroblasts was studied by Pagliarini et al. (Pagliarini et al., 1995) where samples were taken from both human free and attached gingiva. The results demonstrated that the proportion of extracellular sulfated glycosaminoglycan

increased in free gingival fibroblasts, whereas the amount of intracellular sulfated glycosaminoglycan increased in attached gingival fibroblasts.

Kimball (Kimball, 1939) who was the first to detect the enlargement of the gingival tissues as a side effect of phenytoin, had stated that the enlargement is attributed to decrease in blood serum ascorbic acid. Frankel (Frankel, 1940) also stated an association between phenytoin-induced G.O. and ascorbic acid levels.

There is probably a minimal threshold dose of phenytoin where the G.O. does not take place, but it happens that the plasma level of phenytoin necessary to guarantee seizure control exceeds always the minimal threshold dose necessary to induce phenytoin-induced G.O. (Rees, 1993). The therapeutic plasma level of phenytoin necessary to preserve effective seizure control is 10-20 µg/ml. A lot of factors such as metabolism, patient compliance and other medications might interfere with phenytoin plasma levels and, thus, seizure control (Dahllöt and Modéer, 1986).

The enlargement of phenytoin-induced G.O. is presented 2-3 weeks after starting the treatment with phenytoin and reaches the maximum stage in 9-12 months (Walker et al., 1980).

The anterior aspect (i.e., buccal gingiva of the anterior sextants) is the most commonly affected part which usually results in aesthetic distortions (Dallas, 1963; Dreyer and Thomas, 1978). In addition, enlargement of the gingiva might cause malpositioning of teeth and interference with normal physical activities such as mastication and speech (Church et al., 1984). The incidence of phenytoin-induced G.O. is not affected by sex or race (Stinnett et al., 1987).

The overgrowth disappears spontaneously within months after cutting the drug. However, even after surgical removal of G.O., it starts slowly to increase in size.

4.2.2.2. Cyclosporine-induced gingival overgrowth

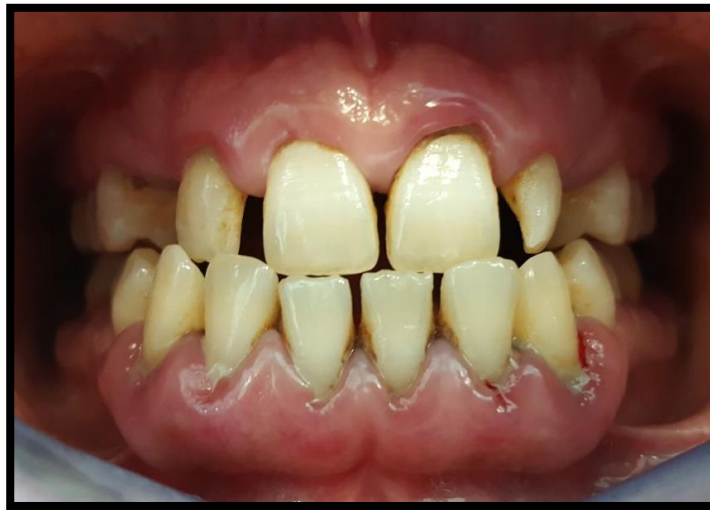In 1970, CsA was isolated for the first time as a metabolite of the fungus type *Tolypocladium inflatum* Gams (Hallmon and Rossmann, 1999). Moreover, it had demonstrated the fact to have little value as an antifungal antibiotic (Hallmon and

Rossmann, 1999). However, CsA is defined as a cyclic polypeptide with powerful immunosuppressive action which extends the survival of allogeneic transplants involving heart, kidney, skin, liver, bone marrow and lung (Hallmon and Rossmann, 1999). The discovery of CsA is referred to Jean Borel (Borel et al., 1995), and its first reported usage was accompanied with renal transplantation by Calne et al. (Calne et al., 1978).

The immunosuppressant CsA suppresses the synthesis and release of interleukin-2 (IL-2) at oral dosages of 10-20 mg/kg/day. It suppresses the capability of cytotoxic T lymphocytes in response to IL-2. While CsA inhibits the synthesis and release of IL-2, it suppresses IL-1 receptors on T helper cells. In addition, CsA has an immunosuppressive efficiency on macrophages. Therefore, CsA is eclectic in its activity on T lymphocytes (Seymour and Jacobs, 1992).

The side effects that results after the usage of CsA are nephrotoxicity, hypertrichosis, hypertension and G.O. Most of these side effects are dependent on the drug's dosage and reversible without any consequences upon discontinuing or decreasing the drug. The incidence of CsA-induced G.O. was first reported in literature by Rateitschak-Plüss et al. (Rateitschak et al., 1983). The mechanism and action of its occurrence is still not well understood. The drug works at an early stage of the treatment on the differentiation of T cells (Borel et al., 1977; White et al., 1979). Helper T cells which plays a role in cellular and humoral immune responses are inhibited selectively and reversibly by CsA. The drug is administered orally or intravenously, and dosages greater than 500 mg/day are responsible to induce G.O. (Daley et al., 1986). It was found that the size of the enlargement seems to be associated with the plasma concentration more than the patient's own periodontal status (Seymour et al., 1987). In a study by Daley et al. (Daley et al., 1986), 100 patients have been observed and evaluated over 2.5 years with 70% of them presenting mild G.O. at least. They suggested that progressive G.O. took place over several months, often reaching a plateau after 1 year of applying CsA treatment (Daley et al., 1986).

Studies reported that children are more frequently affected by this type of enlargement, and have greater risk of developing CsA-induced G.O. (Picture 4.2.), especially young females and adolescents (Seymour and Heasman, 1988; Daley et al., 1986; Hefti et al., 1994; Schulz et al., 1990).



Picture 4.2. Clinical view of CsA-induced G.O.

There might be a correlation between sex hormones, gingival fibroblasts and CsA (Seymour and Jacobs, 1992). The incidence of CsA-induced G.O. varies, according to different studies, from 25% to 70% (Romito et al., 2004). In other studies, authors have suggested that the enlargement has more likelihood to develop when CsA plasma concentration exceeded 400 ng/ml. (Seymour and Heasman, 1988; Hefti et al., 1994). Hefti et al. (Hefti et al., 1994) stated in their study that the incidence of CsA-induced G.O. requires a threshold of CsA in plasma concentration.

The presence of CsA-induced G.O. varies in percentage in each study. These differences appear to be correlated with duration of treatment, CsA dosage, periodontal status, patient's age, medical health status and genetic readiness to be responders or nonresponders (King et al., 1993; Fuiano et al., 1989; Somacarrera et al., 1994; Pernu et al., 1992).

Tyldesley and Roter (Tyldesley and Rotter, 1984) evaluated 36 transplant patients in their study, finding CsA-induced G.O. in nine patients (25%), with males showing less incidence of G.O. (17%) than females (38%). CsA-induced G.O. was more encountered on the anterior buccal aspects of the gingival tissues, and presented great bleeding when it is removed surgically. Phenytoin-induced G.O. is less vascularized compared to CsA-induced G.O. (Rateitschak-pluss et al., 1983; Williams, 2004; Wysocki et al., 1983). Since hypertension's incidence is a widespread finding in renal transplant patients and ranges from 38.5% to 51.2% (Hamilton et al., 1982), patients undergoing both CsA and C.C.B. medications have greater G.O. (Thomas et al., 1992; Thomason et al., 1993; Thomason et al., 1996). Slavin and Taylor (Slavin and Taylor, 1987) reported an increased rate of G.O. in patients under CsA and C.C.B. compared with patients under CsA alone. In addition, O'valle et al. (O'valle et al., 1995) used morphometric analysis to compare patients under CsA treatment only or CsA combined with nifedipine, and reported significant differences in their G.O.'s status. These results were in agreement with other studies by Bökenkamp et al. (Bokenkamp et al., 1994) and Thomason et al. (Thomason et al., 1995). Moreover, in a case report by Rossman et al. (Rossman et al., 1994), authors have stated that replacing another antihypertensive drug instead of nifedipine allowed unmanageable renal transplant patient to have a successful long-term management of G.O.

Wysocki et al. (Wysocki et al., 1983) stated that sensitivity of individuals to the drug or its metabolites might be related to the CsA-induced G.O. The drug and its major metabolite OL-17 could have an interaction with a phenotypically specific subpopulation of gingival fibroblast, resulting in an increase in protein synthesis and cell proliferation (Hassell et al., 1988; Jacobs et al., 1990). The effects of the CsA on normal human fibroblasts were shown to remain unchanged, decrease or increase (Coley and Hassell, 1986).

In 1986, McGaw et al. (McGaw et al., 1987) studied the correlation between CsA-induced G.O. with dental plaque scores, gingivitis scores, and CsA levels in serum and saliva. A significant positive correlation was found between whole saliva CsA, and both G.O. and plaque which were attributed to the possible role of dental

plaque as a local reservoir of CsA. Another significant positive correlation was found between G.O. and dental plaque scores. On the other side, no such significant correlation was found when submandibular CsA or parotid CsA were considered which was related to differences in saliva-collection methods (McGaw et al., 1987).

In 1994, Somacarrera et al. (Somacarrera et al., 1994) studied in a longitudinal study the factors related to the incidence and severity of CsA-induced G.O. in transplant patients. In order to assess the severity and incidence of CsA-induced G.O., this study was conducted following the first six months of transplant surgery in 100 heart, liver, or kidney transplant patients. Blood concentration of CsA, in addition to plaque, gingivitis and G.O. indices were assessed monthly. The percentage of patients developed G.O. was 43%. During the study, plaque and gingivitis decreased significantly due to an oral hygiene training and motivation program while G.O. increased significantly. It was suggested that the main factor causing the incidence of G.O. is the CsA blood concentration.

4.2.2.3. Calcium channel blockers-induced gingival overgrowth

Using C.C.B.s for the treatment of cardiovascular diseases such as hypertension, angina pectoris, cardiac arrhythmias and coronary artery spasms has been introduced in recent years. The classification of these drugs, termed calcium antagonists or C.C.B. might be dependent on the chemical composition as phenylalkylamine derivatives (verapamil), substituted dihydropyridines (amlodipine, nifedipine, felodipine, isradipine, nicradipine, nitrendipine, oxodipine, nisoldipine and nimodipine) or benzothiazepine derivatives (diltiazem) (Hassell and Hefti, 1991; Seymour, 1991). The mechanism of these drugs is based on inhibiting calcium ion flowing across the cell membrane of heart and smooth muscle cells, thereby blocking the intracellular mobilization of calcium. Therefore, inducing direct expansion of the coronary arteries and arterioles and improving oxygen supply to heart muscle. In addition, C.C.B.s also decrease hypertension severity by increasing the peripheral vasculature (Hallmon and Rossmann, 1999).

Some of the C.C.B. drugs can cause G.O. like diltiazem, felodipine, nitrendipine (Brown et al., 1990; Heijl and Sundin, 1989). The most often used C.C.B. is nifedipine (Nishikawa et al., 1991; Hancock and Swan, 1992; Lederman et al., 1984; Lucas et al., 1985) which is the dihydropyridines derivative most oftenly associated with G.O. (Hallmon and Rossmann, 1999), causing G.O. in 20% of the patients (Barclay et al., 1992). A percentage of 15% to 83% of patients under nifedipine treatment was reported to express G.O. as a side effect (Barclay et al., 1992; Slavin and Taylor, 1987; Barak et al., 1987; Fattore et al., 1991). In addition, 4% of patients taking verapamil (Miller and Damm, 1992) and 21% of patients taking diltiazem (Steele et al., 1994) expressed G.O.

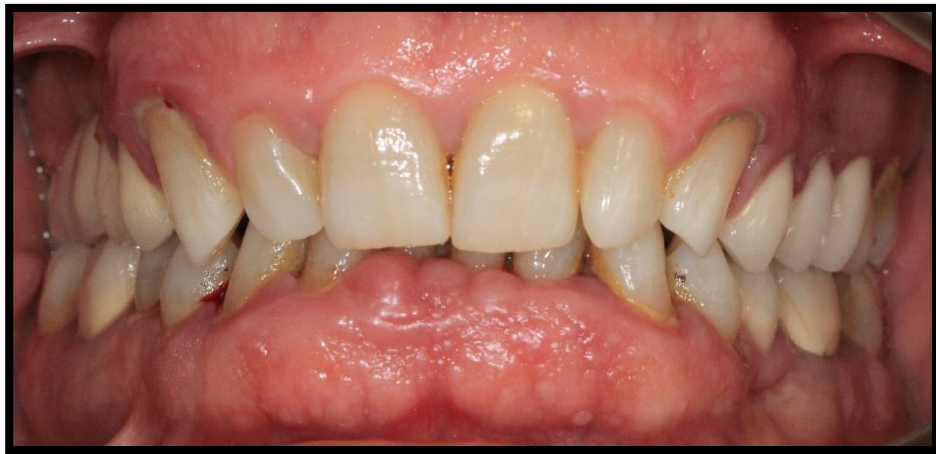In 1995, Nery et al. (Nery et al., 1995) stated in their study that 43.6% among 181 patients under nifedipine had G.O. as compared with 4.2% in 71 control patients who were not taking phenytoin, CsA or C.C.B. In addition, this percentage (43.6%) reported by Nery et al. compares favorably with the composite average (42.5%) of several studies (Barclay et al., 1992; Barak et al., 1987; Fattore et al., 1991; Shibley et al., 1994) (Hallmon and Rossmann, 1999).

Ellis et al. (Ellis et al., 1993) reported that 9 patients under nifedipine therapy (40 to 80 ng/ml) for at least 6 months demonstrated nifedipine levels in both the gingival crevicular fluid and plasma. Four of the patients were unaffected by the drug (non-responders) while five patients had notable G.O. (responders). Interestingly, seven out of nine patients had nifedipine concentration in the gingival crevicular fluid 15 to 316 times greater than plasma levels (Ellis et al., 1993).

Thomason et al. (Thomason et al., 1995) studied cardiac transplant patients who were mediated with both CsA as an immunosuppressive drug and nifedipine as a C.C.B., marked levels of nifedipine have been detected in gingival crevicular fluid. Nevertheless, the gingival changes had no obvious relationship with the gingival crevicular fluid levels nor to the nifedipine plasma concentration (Thomason et al., 1995).

Amlodipine which is a substituted dihydropyridine and an anti-anginal C.C.B. acts by decreasing myocardial contractility and oxygen demand which expands coronary arteries and arterioles (Thomason et al., 1995).

In humans, nifedipine-induced G.O. (Picture 4.3) dose dependency is not clear. Adversely, nifedipine-induced G.O. has been induced experimentally in rats where its dose dependency is clear (Fu et al., 1998). Nifedipine is also accompanied with CsA in kidney transplant patients where the combination between both drugs induce larger enlargements (Bokenkamp et al., 1994). One study states that nifedipine increases the risk of periodontal destruction in patients with type 2 diabetes mellitus (Li et al., 2008).



Picture 4.3. Clinical view of nifedipine-induced G.O.

4.2.3. Enlargements associated with systemic diseases

Different systemic diseases and conditions develop oral manifestations that may include G.O.

4.2.3.1. Conditioned gingival overgrowth

Conditioned G.O. occurs when the systemic condition of the patient exaggerates the normal response of the gingiva to dental plaque. The difference between conditioned G.O. and chronic gingivitis depends on the nature of the modifying

systemic influence. Dental plaque is not the only determinant of the clinical manifestation, but it is compulsory for the starting of this type of G.O.

4.2.3.1.1. Gingival overgrowth in vitamin C deficiency

It has been suggested that vitamin C deficiency/scurvy is associated with gingival inflammatory changes; however, the disorder is very infrequently encountered in the modern era (Carranza et al., 2015). The condition itself does not cause an inflammatory process in the gingival tissues, but rather bring out hemorrhage, connective tissue edema, and collagen degeneration (Carranza et al., 2015). Therefore, the gingival inflammatory response to dental plaque is exaggerated and the normal defensive reaction is inhibited (Glickman, 1948). Clinically, this type of G.O. occurs marginally with a soft and friable consistency, and a bluish red color. Hemorrhage might be spontaneously presented, or may occur on mild provocation. Necrosis with pseudomembrane are also common features of this condition (Carranza, 2015).

4.2.3.1.2. Gingival overgrowth in pregnancy

During pregnancy, there is an increase in level of progesterone which reaches by the end of the third trimester a level 10 times more the level presents during the menstrual cycle. In addition, estrogen also increases at this time period to reach a level 30 times higher than the level presents at the menstrual cycle (Amar and Chung, 1994). These hormonal changes cause alterations in vascular permeability, which leads to gingival edema and an increased inflammatory response to factors such as dental plaque. Changes also apply on subgingival microbiota, including an increase in *Prevotella intermedia* (Kornman and Loesche, 1980; Raber-Durlacher et al., 1994).

This type of G.O. might be marginal or generalized, or it may present as a single mass or multiple tumor-like masses (Carranza, 2015).

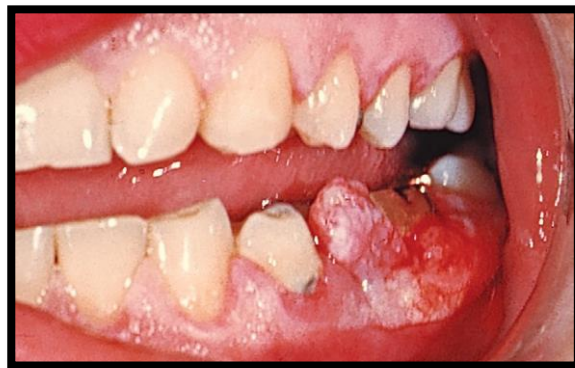4.2.3.1.2.1. Marginal gingival overgrowth in pregnancy

During pregnancy, marginal G.O. appears clinically, and its features vary in a considerable manner. It is usually generalized and has a tendency to be more notable

in interproximal areas rather than on the labial or lingual surfaces. The enlarged gingiva is bright red in color, soft, friable, and has a smooth, shiny surface. It occurs as a result of aggravation of a previous inflammatory process, reporting an incidence as 10% (Burket, 1946) and 70% (Ziskin and Stout, 1933). The presence of bleeding is spontaneous or upon a slight provocation.

4.2.3.1.2.2. Tumor-like gingival overgrowth in pregnancy

During pregnancy, tumor-like G.O. appears clinically as a discrete, mushroomlike, flattened spherical lesion that emerges from the margin of the gingiva, or more frequently from the interproximal space, and it is connected by a pedunculated base or a sessile (Picture 4.4). The lesion has dusky red or magenta color. The surface is smooth, glistening that usually presents abundant deep-red, pinpoint markings. This type of lesions is superficial without any invasion to the underlying bone. The lesion expands laterally and pressure from the tongue and cheek preserves its flattened manifestation. The mass is usually semifirm, but it might have varying grades of softness and flakiness. The lesion is painless unless there is accumulation of debris under its margin or interference with occlusion, in which case painful ulceration might present (Carranza et al., 2015).

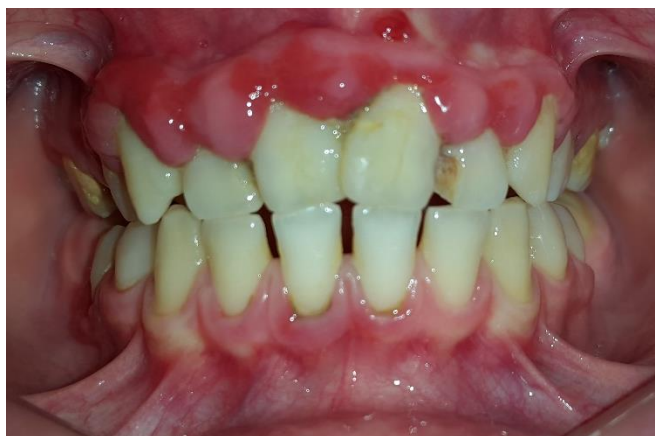

Picture 4.4. Clinical view of G.O. in pregnant woman (Carranza et al., 2015)

4.2.3.1.3. Gingival overgrowth in puberty

In puberty, G.O. (Picture 4.5) occurs in both male and female adolescents, and is presented in dental plaque accumulation areas. The facial aspect of the gingiva is usually enlarged, and the lingual aspect is comparably unaltered due to the mechanical activity of the tongue and the excursion of food prevent the intensive accumulation of irritants on the lingual surface. The enlargement extends to the marginal and interdental gingiva with prominent bulbous interproximal papillae, greatly surpassing that seen in correlation with comparable local factors (Carranza et al, 2015).

Clinically, G.O. during puberty has the same clinical features that is observed with a chronic inflammatory gingival disease. The enlargement of gingival tissues during puberty is distinguished through the degree of enlargement and the inclination for recurrence with little amounts of dental plaque deposits. After puberty, G.O. declines spontaneously, but without a complete disappearance until the local irritants as dental plaque or calculus are removed. A longitudinal study of the subgingival microbiota of children between 11 and 14 years old and their correlation with clinical parameters indicated *Capnocytophaga* in the initial level of pubertal gingivitis (Mombelli et al., 1990). On the other hand, it was reported in other studies that an increase in the proportion of *Prevotella intermedia* and *Prevotella nigrescens* coincide with an increase in hormonal changes (Nakagawa et al., 1994; Wojcicki et al., 1987).



Picture 4.5. Clinical view of pubertal G.O.

4.2.3.1.4. Plasma cell gingivitis

Plasma cell gingivitis is a mild G.O. in the marginal gingiva that extends to the attached gingiva. Clinically, the gingiva has a red color, with a friable, and sometimes granular manifestation. There is no attachment loss, and the gingiva bleeds easily. The lesion differs from the plaque-induced gingivitis since it is located in the attached gingiva. It is thought that plasma cell gingivitis is originally allergic to some diet components such as chewing gum. Therefore, taking off of these allergic materials brings resolution of the lesion (Carranza et al., 2015).

4.2.3.2. Systemic diseases that cause gingival overgrowth

4.2.3.2.1. Wegener's granulomatosis

Wegener's granulomatosis is characterized by acute granulomatous necrotizing lesions of the respiratory tract, including both nasal and oral defects. After development of renal lesions, blood vessels are affected by acute necrotizing vasculitis. The primary appearances of Wegener's granulomatosis might include oral mucosal ulceration, abnormal tooth mobility, exfoliation of teeth, delayed healing response (Buckley et al., 1987), and G.O. (Hernandez et al., 2008). Clinically, the lesion has a reddish purple color, and bleeds easily on stimulation (Carranza et al., 2015).

4.2.3.2.2. Sarcoidosis

Sarcoidosis is a granulomatous disease that initiates in individuals during their 20s or 30s of unknown etiology. It can involve any organ including the gingiva. Clinically, it appears as a red, smooth, painless G.O. (Carranza et al., 2015).

4.2.3.2.3. Leukemia

Leukemias are a group of life threatening malignant disorders of the blood and bone marrow (Juliusson et al., 2016). Clinically, the gingiva has a bluish red color with

a shiny surface. It is moderately firm, but there is an inclination toward friability. Bleeding occur either spontaneously or with mild provocation. Simple chronic inflammation without the involvement of leukemic cells might occur. Interestingly, the same clinical and microscopic features seen in patients without the systemic disease might present. However, most of the cases show the features of both simple chronic inflammation and leukemic infiltrate. True leukemic G.O. usually presents with acute leukemia, but it may be also presented with subacute leukemia. It rarely occurs with chronic leukemia (Carranza et al., 2015).

4.2.4. Idiopathic gingival overgrowth

Idiopathic G.O. is a rare condition of unspecific cause. The overgrowth affects the attached gingiva, gingival margin and the interdental papillae. (Carranza et al., 2015). Idiopathic G.O. is specified by such terms as *idiopathic fibromatosis, gingivostomatosis, elephantiasis, and congenital familial fibromatosis*. The buccal and lingual surfaces of both jaws are affected, but the involvement might exceed to either jaw. Clinically, the gingiva looks pink in color, firm, and almost leathery in its uniform. Secondary inflammatory changes occur commonly due to plaque accumulations at the marginal gingiva (Carranza et al, 2015). In severe cases of idiopath G.O., the teeth are almost covered and the jaws have a distorted appearance as a result of the bulbous overgrowth of the gingiva (Carranza et al, 2015).

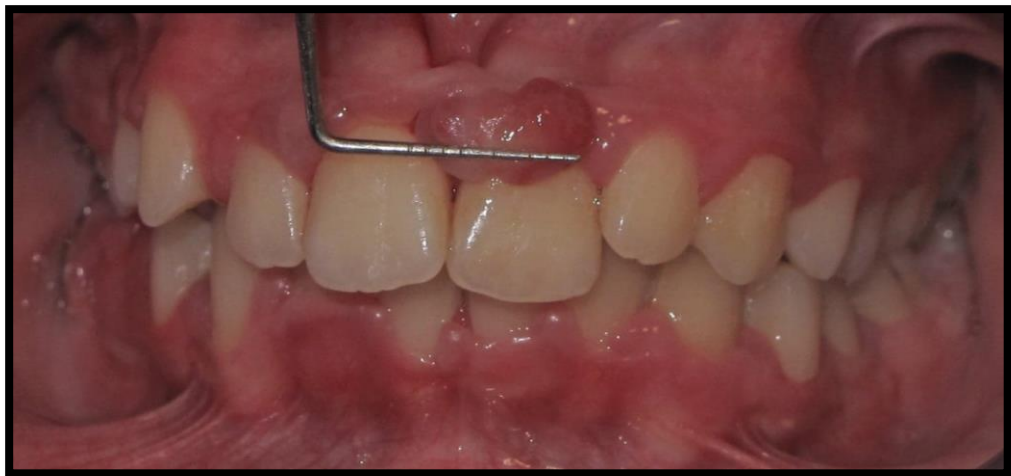The etiology of this kind of G.O. is unknown, and thus it is specified as “idiopathic”. Hereditary basis had been found in some cases (Wysocki et al., 1983; Emerson, 1965; Zackin and Weisberger, 1961), but the genetic mechanisms are not well understood. A study of numerous families focusing on the enlargement found the inheritance to be autosomal dominant in some cases and autosomal recessive in other ones (Raeste AM et al., 1978; Jorgenson and Cocker, 1974). It is found that idiopathic G.O. is attributed to weakness in physical development (Klipinen et al., 1978). The beginning of the overgrowth starts with the eruption of the primary or secondary dentition, and regression of the overgrowth occur after extraction, which suggests the teeth or plaque attached to them are launching factors for this type of overgrowth.

Secondary inflammatory process could also start due to the accumulation of dental plaque (Carranza et al, 2015).

4.2.5. Neoplastic enlargement

4.2.5.1. Benign tumors

Epulis is a generic term that is used clinically to designate all discrete tumors and tumor-like masses of the gingiva as it is shown in Picture 4.6. It serves to locate the tumor but not to describe it. Most lesions referred to by this term are inflammatory rather than neoplastic. Neoplasms account for a comparatively small proportion of gingival enlargements, and they make up a small percentage of the total number of oral neoplasms. Examples of benign tumors are fibroma, papilloma, central giant cell granuloma, hemangioma, myoblastoma, neurilemoma, and ameloblastoma (Carranza et al, 2015).



Picture 4.6. Clinical view of an epulis.

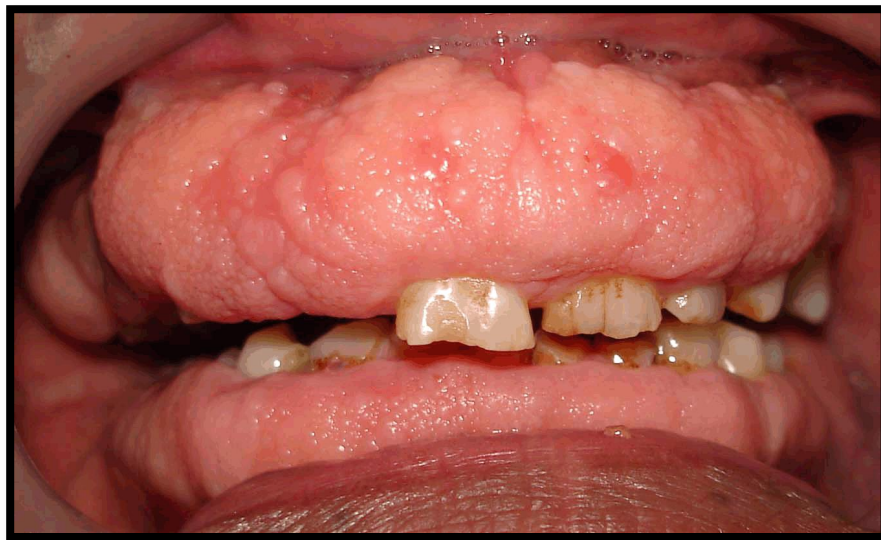4.2.5.2. Malignant tumors

Oral cancers account for less than 3% of all malignant tumors in the body, but it is the sixth most common cancer in males, and the twelfth most common cancer in females. The gingiva is not a very frequent site for malignancy, accounting for only

6% of oral cancers. Examples are squamous cell carcinoma, malignant melanoma, fibrosarcoma, and lymphosarcoma (Carranza et al, 2015).

4.2.6. Hereditary gingival fibromatosis

Hereditary gingival fibromatosis (H.G.F.) is a rare benign oral condition characterized by slow and progressive enlargement of both maxillary and mandibular attached gingiva as it is shown in Picture 4.7. It may develop as an isolated disorder but can feature along with a syndrome (Carranza et al, 2015).



Picture 4.7. Clinical view of H.G.F.

4.3. Treatment of Gingival Overgrowth

The treatment of G.O. is based on the cause and the pathologic factors of this clinical manifestation (Carranza et al., 2015). Since G.O. varies according to the causing factors, treatment of each kind of G.O. is best considered individually (Carranza et al., 2015)

4.3.1. Treatment of chronic inflammatory gingival overgrowth

Chronic inflammatory G.O. is treated by scaling and root planing. When chronic inflammatory G.O. have a fibrotic component which does not shrink after initial periodontal treatment or of a big size that overlap with the complete removal of deposits on the tooth surfaces, surgical removal of the enlarged gingival tissues must be done (Carranza et al., 2015). As a surgical process, two techniques can be done: gingivectomy and flap operation (Carranza et al., 2015). When G.O. is friable even after initial periodontal treatment, the clinician must select gingivectomy as the choice of surgical treatment because deciding to operate with a flap surgery needs firmer type of gingival tissues (Carranza et al., 2015). Flap surgery is indicated when gingivectomy might affect the width of the attached gingiva.

4.3.2. Treatment of drug-induced gingival overgrowth

The treatment of drug-induced G.O. depends on the type of medical drug being used (Carranza et al., 2015). Discontinuing the medication causing G.O. must be put into first consideration (Dongari et al., 1993; Harel-Raviv et al., 1995). Discontinuing the medication is not procedural, but its replacement with different drug might be a solution (Carranza et al., 2015). All these potentials must be regarded under patient's physician consultation (Carranza et al., 2015).

In cases of phenytoin-induced G.O., carbamazepine (Dahllof et al., 1993) and valproic acid are alternative drugs to phenytoin. In cases of drug-induced G.O. due to C.C.B., diltiazem or verapamil which have prevalence 20% and 4% respectively, might be alternatives to nifedipine which has a higher prevalence of G.O. up to 44%, (Barclay et al., 1992; Fattore et al., 1991; Nery et al., 1995). Nifedipine can be replaced by another dihydropyridine derivative (Isradipine) which does not induce G.O. (Westbrook et al., 1997). In cases where patients are taking CsA, tacrolimus is also an immunosuppressant which is prescribed to organ transplant patients (Sekigucchi et al., 2007,). The occurrence of G.O. in patients under the immunosuppressant tacrolimus is around 65% less than patients under CsA (Argani et al., 2006). In cases of individuals

who are under the treatment of both CsA and a C.C.B., G.O. tends to be less severe if amlodipine was used as an anti-hypertensive medication compared with nifedipine (Lopez et al., 2009). It has been shown that a 3-day course of azithromycin lowered the G.O., and the result was observed as 7 days to 1 month after the initiation of azithromycin treatment (Tokgoz et al., 2004).

Although the specific role done by bacterial plaque is not well understood, it is proposed that chemotherapeutics (Saravia et al., 1990), good oral hygiene, and the professional plaque removal decrease G.O.'s severity and enhance the health of the gingiva (Dongari et al., 1993; Hall, 1969; Seymour and Jacobs, 1992). Pseudopockets are formed in cases of drug-induced G.O with accumulated plaque deposits leading to the development of periodontitis; plaque control helps to preserve attachment levels and to prevent any recurrence in surgically treated cases (Carranza et al., 2015).

In some individuals, G.O. still exist after all these previously mentioned treatment trials. These individuals might need surgery, which include gingivectomy or periodontal flap (Carranza et al., 2015).

Gingivectomy is a simple and quick operation but presents disadvantages like discomfort or bleeding postoperatively (Carranza et al., 2015). Furthermore, gingivectomy sacrifices keratinized tissue, and does not include any bone surgery for osseous recontouring (Carranza et al., 2015). Electrosurgery or laser device can be used to perform gingivectomy or gingivoplasty (de Oliveira et al., 2010). When drug-induced G.O. is treated via laser, the recurrence is slower compared with conventional surgeries (Mavrogiannis et al., 2006).

Flap technique is used in areas when G.O. include more than 6 teeth or areas with attachment loss and osseous defects exist (Carranza et al., 2015). The flap technique may be a harder procedure than gingivectomy, but it has less discomfort and hemorrhagic problems postoperatively (Carranza et al., 2015). In addition, the primary closure obtained with the flap technique is a great feature over the secondary open injury that results after gingivectomy (Carranza et al., 2015).

4.3.3. Treatment of gingival overgrowth during pregnancy

The treatment of G.O. during pregnancy includes the removal of all local irritants as a preventive procedure before the gingival disease occurs (Carranza et al., 2015). The treatment of the inflammation is done by scaling and curettage. In cases of tumor-like G.O., surgical excision can be done in combination with scaling and root surface planning (Carranza et al., 2015). A surgical removal of the lesions should be performed during pregnancy only if there is an interference with mastication or a aesthetic concern (Carranza et al., 2015).

4.3.4. Treatment of gingival overgrowth during puberty

The treatment of G.O. during puberty includes initial periodontal treatment such as scaling and curettage, the removal of all local irritants, and applying plaque control procedures (Carranza et al., 2015). In severe cases, surgical removal of lesions is indicated (Carranza et al., 2015).

4.4. Gingival Overgrowth Indices

The evaluation of G.O., and the classification of its degrees and stages have been always a matter of interest. Authors have used various methodologies in order to estimate the level of severity of the enlargement through their studies. The articles were concerned about different types of G.O., and the relationship between its incidence and the causing factors. In order to assume G.O.'s severity and classify its degrees, different indices have been put. Some indices were described on the basis of intra-oral clinical examination. On the other hand, other indices were accomplished with support of other means such as plaster models, photographs, etc.

The indices used for G.O.'s evaluation differentiate in their origin; some of them were described by the same authors discussing the concerned G.O.'s subject, others were modified in the sequence and order of G.O.'s stages, and others have modifications in the measuring means.

4.4.1. Intra oral measurements

4.4.1.1. Kimball index

In 1939 Kimball (Kimball, 1939) was the first author to describe G.O. as an adverse effect to sodium diphenyl hydantoin of epileptic patients. Kimball emphasized the better general health, mental state and personality after using diphenyl hydantoinate with pointing to the development of giddiness, sore mouth and a staggering gait as noticed general side effects. It was also found that G.O. had developed and extended to a stage that suggested scurvy. Kimball divided the 152 patients taking diphenyl hydantoinate in his report into two groups: 119 have been examined with G.O., and 33 were not. Fifty-one out of 119 were classified as normal and sixty-eight presented diverse degrees of G.O. Kimball pointed out that severe G.O. was found in 17 patients.

In order to examine this unusual observation, Kimball (Kimball, 1939) mentioned in his article the grading of G.O. as been described by different studies, without citing them, which were made on thirty-four children to compare between the degree of the G.O. and the ascorbic acid in the blood serum as shown in Table 4.3.

Table 4.3. Classification of G.O. by Kimball (Kimball, 1939)

Gingival hyperplasia	Description
Normal	No changes in the gingiva
One plus	Definite hyperplasia
Two plus	Advanced hyperplasia
Three plus	Extreme hyperplasia

4.4.1.2. Frankel index

In 1940, Frankel (Frankel, 1940) had examined 48 epileptic patients who were receiving either phenobarbital or bromide or both for long time. Frankel discussed the G.O. using the index reported by Kimball as moderate, advanced and extreme.

4.4.1.3. Robinson index

In 1942, J. Robinson (Robinson, 1942) made an evaluation of continued therapy with phenytoin sodium and phenobarbital, and mentioned the toxic reactions encountered in patients subjected to treatment. Robinson (Robinson, 1942) discussed in details the gingival changes occurring since they are frequently encountered. In another report, Robinson (Robinson, 1942) presented thoroughly the gingival changes accompanying the application of phenytoin sodium. The gingival appearance ranged between redness to different degrees of hyperplasia. Robinson graded the G.O. into five stages as shown in Table 4.4.

Table 4.4. Classification of G.O. by Robinson (Robinson, 1942)

Gingival hyperplasia	Description
Stage 1	Redness
Stage 2	Elevation
Stage 3	Elevation
Stage 4	Frangibility
Stage 5	Interference with chewing

4.4.1.4. Harris and Ewalt index

In 1942, Harris and Ewalt (Harris and Ewalt, 1942) studied the complications following the use of sodium diphenyl-hydantoinate therapy. The gingival hyperplasia as a side effect has a variation in its severity ranging from a slight reddening of the gingival margin to a definite marginal hyperplasia. In this literature Harris and Ewalt

had classified the changes occurring in the gingiva according to severity into five grades as it was classified by Leon J. Robinson in 1942 (Robinson, 1942) as shown in Table 4.5.

Table 4.5. Classification of G.O. by Harris and Ewalt (Harris and Ewalt, 1942)

Gingival hyperplasia	Description
Grade 1	The gums are reddened at the gingival margin, but are not raised and do not bleed
Grade 2	Elevation of the gingival tissues between the adjacent teeth. The condition is painless and does not bleed
Grade 3	The area along the dental margin is raised. There is no bleeding and no pain
Grade 4	The gingiva is fungated and the G.O. is generalized. The hyperplastic tissues might bleed, but the condition is not painful, and it is also unnoticed in children
Grade 5	The anterior and posterior surface of the teeth are covered by extensive G.O. The teeth may be buried, and chewing becomes painful. The gingival tissues might bleed upon touch or where it is bitten by the underlying teeth

Each of the five grades mentioned above were followed by its own management protocol as the following:

- Grade 1: This is the type of gingival hyperplasia that is encountered in the majority of patients. Treatment with the drug may be continued, but observation and following of the patients should be frequent.
- Grade 2: The dilatin should be discontinued if the patients have this complication and maintenance on phenobarbital can be achieved.
- Grade 3: The authors advice that the drug should be withdrawn as the continuous usage of this drug usually produces one of the more advanced and severe grades.

- Grade 4: Withdrawing of the drug.
- Grade 5: Withdrawing of the drug.

4.4.1.5. Aas index

In 1963, Aas (Aas, 1963) studied the clinical, histological, and biochemical of “hyperplasia gingivae diphenylhydantoinea”. In order to assess G.O., Aas described an index by dividing the quadrants into sextants, and was graded as the following:

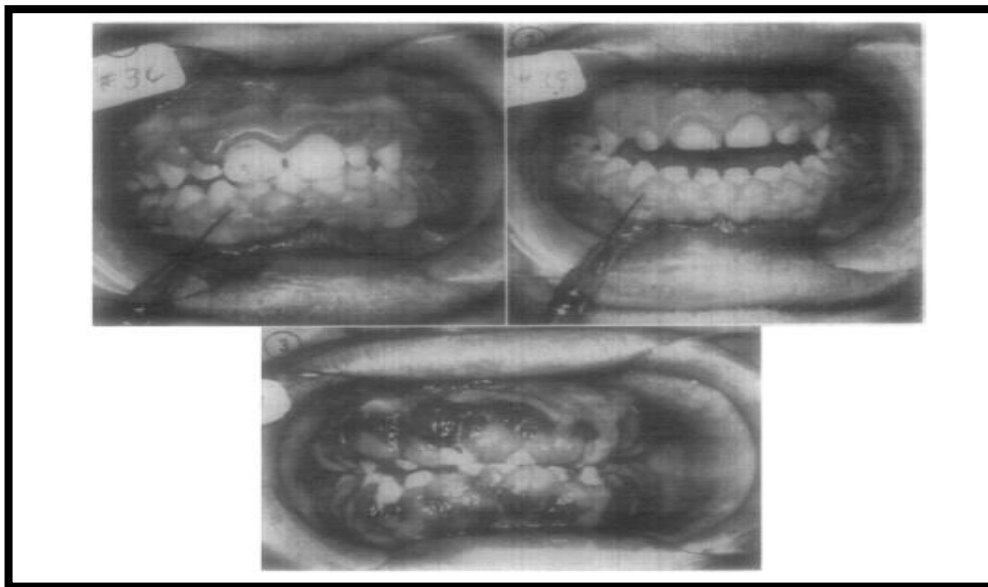
- Grade 0: No G.O., the gingiva follows a normal contour on all teeth
- Grade 1: Slight or moderate G.O. The interdental papillae have assumed a more rounded blunt form; the gingival margin is slightly thickened. The anatomical crowns are covered up to one-third of the vestibular surfaces.
- Grade 2: Marked G.O., The papillae and the gingival margin cover from one-third to one-half of the vestibular surfaces. In most cases, the papillae is separated only by a V-shaped cleft.
- Grade 3: Severe G.O. The gingiva propria covers one-half to two-thirds of the vestibular surfaces and protrudes 3-4 mm from the surface of the teeth.
- Grade 4: Very severe G.O. The hyperplastic tissue covers from two-thirds to the whole of the anatomical crowns in one or more regions, and occlusion is rendered difficult, if not prevented.

4.4.1.6. Angelopoulos and Goaz index

In 1972, Angelopoulos and Goaz (Angelopoulos and Goaz, 1972) studied the incidence of G.O. in epileptic patients under the treatment of diphenylhydantoinate. They graded the gingival hyperplasia and recorded it according as it is shown in Table 4.6. and as described in Picture 4.8.

Table 4.6. Classification of G.O. by Angelopoulos and Goaz (Angelopoulos and Goaz, 1972)

Gingival hyperplasia	Description
Grade 0	No hyperplasia; Normal gingiva
Grade I	The hyperplastic gingiva covered the cervical third of the anatomic crowns or less of the anterior teeth
Grade II	The hyperplastic gingiva extended anywhere in the middle third of the anatomic crowns of the anterior teeth
Grade III	The hyperplastic gingiva covered more than two thirds of the anatomic crowns of the anterior teeth



Picture 4.8. Classification of G.O. by (Angelopoulos and Goaz); Grade I gingival hyperplasia; Grade II gingival hyperplasia; Grade III gingival hyperplasia (Angelopoulos and Goaz, 1972)

4.4.1.7. Conard et al. index

In 1974, Conard et al. (Conard et al., 1974) measured the levels of 5, 5-diphenylhydantoin and its para-hydroxy metabolite in saliva, serum and gingival hyperplasia segments from patients receiving the drug. Tissues with gingival hyperplasia were taken from 12 patients who are going under partial or complete

therapeutic gingivectomies. Tissues with G.O. were surgically removed in segments from four to six teeth, and each of the hyperplastic gingival segments was graded from grade 0 which indicates no clinical signs of G.O. to grade 4 which indicates that the teeth were completely covered by the enlarged gingival tissues.

4.4.1.8. Addy et al. index

In 1983, Addy et al. (Addy et al., 1983) converted Harris and Ewalt index (Harris and Ewalt, 1942) to be 3 grades rather than 5 grades system. The index used was described as it is shown in Table 4.7.

Table 4.7. Classification of G.O. by Addy et al. (Addy et al., 1983)

Grade	Description
Minimal	No hyperplasia or early hyperplasia evidenced by an increased density of the gingiva with marked stippling and granular appearance
Moderate	Hyperplasia with an increase in the size of the papilla and/or rolled gingival margins
Severe	Marked hyperplasia demonstrating encroachment of the gingiva onto the clinical crown or profound thickening of the gingiva covering a large percentage of the clinical crown

4.4.1.9. Daley et al. index

In 1986, Daley et al. (Daley et al., 1986) studied the clinical and pharmacologic correlations in CsA-induced G.O. The degree of overgrowth was scored in a numerical grade. At each oral examination, G.O. was graded by assigning a score to each interdental papilla on the buccal/labial and lingual/palatal sides.

The G.O.'s scores criteria ranged from 0 as no clinical evidence of non-inflammatory hyperplasia to 5 which indicates an overgrowth overlaying at least three fourths of the clinical crown. In order to measure the G.O.'s score at each patient's

visit, the sum of the raw scores was divided by the number of interdental papilla examined.

4.4.1.10. McGaw et al. index

In 1986, McGaw et al. (McGaw et al., 1987) studied the correlation between CsA-induced G.O. with dental plaque scores, gingivitis scores, and CsA levels in serum and saliva. Thirty renal transplant patients undergoing CsA were enrolled in the study. The G.O. was assessed by means of a modified semiquantitative index developed by Aas (Aas, 1963) as shown in Table 4.8.

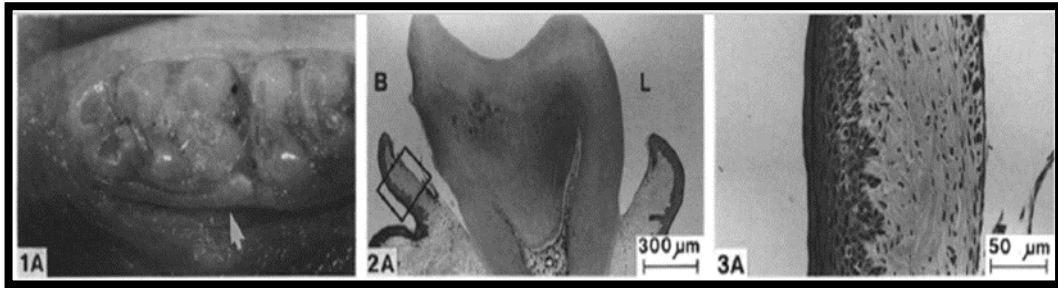
Table 4.8. Classification of G.O. by McGaw et al. (McGaw et al., 1987)

Grade	Criteria
Grade 0	No gingival overgrowth, feather-edged margins of the gingiva
Grade 1	Blunting of the gingival margins
Grade 2	Moderate grade of gingival overgrowth (<1/3 of crown length)
Grade 3	Marked grade of gingival overgrowth (>1/3 of crown length)

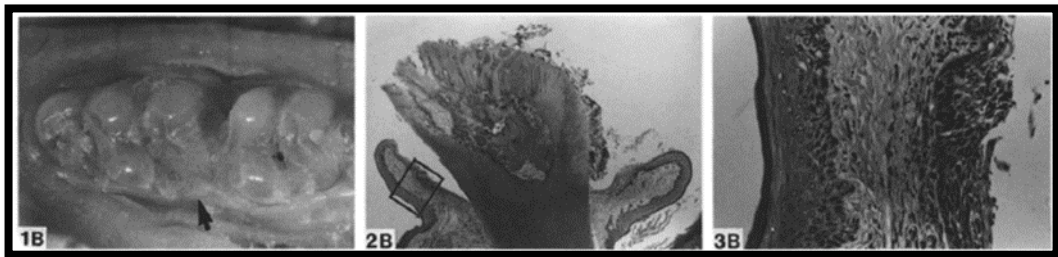
4.4.1.11. Kitamura et al. index

In 1990, Kitamura et al. (Kitamura et al., 1990) studied CsA-induced G.O. in rats. The authors stated that the mechanisms of such side effects as G.O. due to CsA still remain unclear because of the difficulty in reproducing G.O. in experimental animals, especially rodents. The only species in which CsA-induced G.O. could be achieved experimentally were beagle dogs (Seibel et al., 1987). The authors described a rat model for this G.O. The rats were distributed into 4 groups which contain 5 rats in each group (A, B, C, and D) as it is described in Pictures 4.9-4.12 respectively, and the severity of G.O. surrounding mandibular molars was measured from the gingival margin's top to the bottom end of the gingival sulcus with a probe comprising a strip of color-slide film (approximately 250 µm wide) on which were printed 50 µm bands

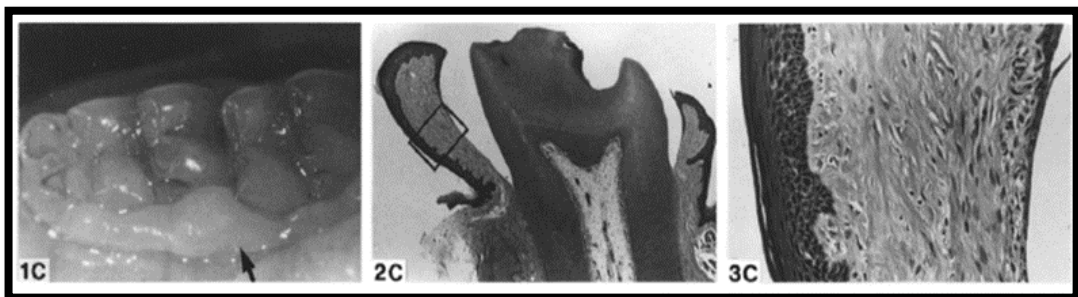
of five different colors. This probe was inserted into the gingival sulcus with light force (about 15 g) under a stereoscopic dissecting microscope.



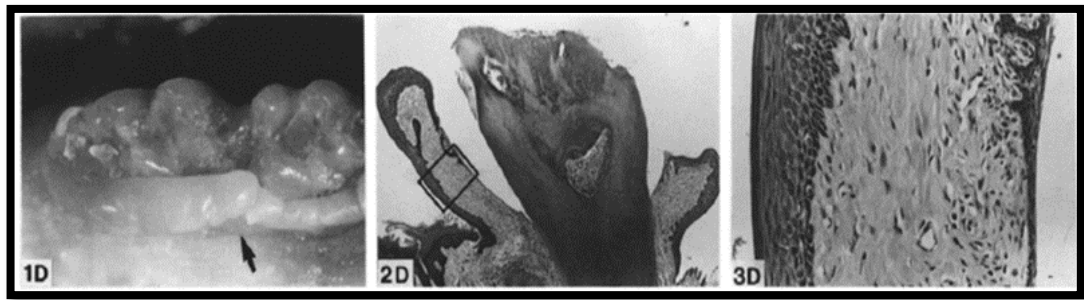
Picture 4.9. Group A in Kitamura et al. study. Rats fed diet No. 2000 without infection. Bucco-lingual sections of corresponding mandibles decalcified and stained with hematoxylin and eosin. Higher magnification micrographs of the zones indicated (x 30) (Kitamura et al., 1990)



Picture 4.10. Group B in Kitamura et al. study. Rats infected with *Strep Sobrinus* 6715 and fed diet No. 2000. Bucco-lingual sections of corresponding mandibles decalcified and stained with hematoxylin and eosin (x 30). Higher magnification micrographs of the zones indicated (x 190) (Kitamura et al., 1990).



Picture 4.11. Group C in Kitamura et al. study. Rats fed diet No. 2000 containing CsA without infection. Bucco-lingual sections of corresponding mandibles decalcified and stained with hematoxylin and eosin shows that the buccal gingiva (left) thickened and elongated towards the crown of the tooth (x 30). Higher magnification micrographs of the zones indicated shows an increased amount of connective tissue without a marked increase in the numbers of fibroblasts or inflammatory cells (x 190) (Kitamura et al., 1990).



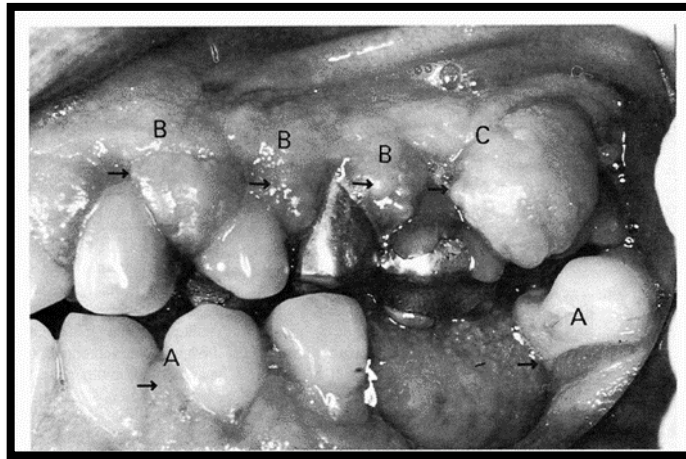
Picture 4.12. Group D in Kitamura et al. study. Rats infected with *Strep Sobrinus* 6715 and fed diet No. 2000 containing CsA. Bucco-lingual sections of corresponding mandibles decalcified and stained with hematoxylin and eosin shows that the buccal gingiva (left) thickened and elongated towards the crown of the tooth (x 30). Higher magnification micrographs of the zones indicated shows an increased amount of connective tissue without a marked increase in the numbers of fibroblasts or inflammatory cells (x 190) (Kitamura et al., 1990).

4.4.1.12. Pernu et al. index

In 1992, Pernu et al. (Pernu et al., 1992) examined G.O. patients among renal transplant recipients related to immunosuppressive medication and analyzed possible local background factors. The degree of G.O. was measured according to a modified criteria of Angelopoulos and Goaz index (Angelopoulos and Goaz, 1972) and classified into 4 categories as it is shown in Table 4.9 and Picture 4.13.

Table 4.9. Classification of G.O. by Pernu et al. (Pernu et al., 1992)

Grade	Description
Grade 0	No gingival overgrowth
Grade 1	Mild gingival overgrowth; lobular granulation of the gingival pocket; thickening of the marginal gingiva; the overgrowth covering the gingival third of the crown or less
Grade 2	Moderate gingival overgrowth; overgrowth extending to the middle third of the crown
Grade 3	Severe gingival overgrowth; overgrowth covering two thirds of the crown or the whole attached gingiva is affected



Picture 4.13. Classification of G.O. by Pernu et al.; A: score 1; B: score 2; C: score 3 (Pernu et al., 1992).

4.4.1.13. Miller and Damm index

In 1992, Miller and Damm (Miller and Damm, 1992) studied the incidence of verapamil-induced G.O. In order to assess the severity of the gingival tissues' enlargement, Miller and Damm identified G.O. depending on location, and used a modified index which was originally depicted by Angelopoulos and Goaz (Angelopoulos and Goaz, 1972). Gingiva's height was measured starting from the cemento-enamel junction to the free gingival margin. On the other hand, gingiva's width was measured from the enamel tooth surface to the gingiva's buccal margin as shown in Table 4.10.

Table 4.10. Classification of G.O. by Miller and Damm

Grade	Description
Grade 0	No G.O., indicating normal gingival tissues
Grade 1	Minimal G.O., less than 2 mm gingival tissues increase in size, and gingiva covers the cervical third or less of the anatomical crown
Grade 2	Moderate G.O., 2 to 4 mm increase in gingival tissues' size, and/or it extends into the middle third of the anatomical crown
Grade 3	Severe G.O., nodular G.O. greater than 4 mm increase in size, and/or gingival tissues cover more than two thirds of the clinical crown

4.4.1.14. Somacarrera et al. index

In 1994, Somacarrera et al. (Somacarrera et al., 1994) studied in a longitudinal study the factors related to the incidence and severity of CsA-induced G.O. in transplant patients. In order to assess the severity and incidence of CsA-induced G.O., this study was conducted following the first six months of transplant surgery in 100 heart, liver, or kidney transplant patients. The degree of G.O. was measured and graded numerically according to the Harris and Ewalt index (Harris and Ewalt, 1942). The study by Somacarrera et al. stated that scores ranged from 0, indicating no clinical evidence of G.O., to 4, indicating G.O. covering at least $\frac{3}{4}$ of the total clinical crown.

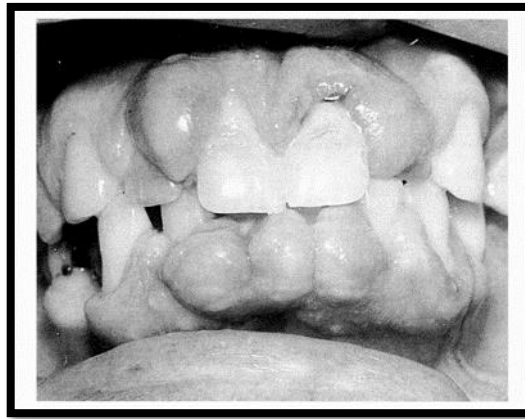
4.4.1.15. Nery et al. index

In 1995, Nery et al. (Nery et al., 1995) studied the prevalence of nifedipine-induced G.O. by employing a much larger sample than the previous studies concerning the same subject. The study included the investigation of the relationship between G.O. and different factors.

In this study, two methods were used to measure the severity of G.O. Firstly, subjects that have normal dentition, G.O. was classified as it is shown in Table 4.11 and Picture 4.14. where the characteristic prominent papillary lesion and the firm gingiva with nodular appearance are noted (Nery et al., 1995).

Table 4.11. Classification of G.O. by Nery et al. in dentate subjects (Nery et al., 1995)

Grade	Description
Grade 0	No gingival overgrowth
Grade 1	Light gingival overgrowth at the cervical third and/or interproximal area of the anatomic crown
Grade 2	Moderate gingival overgrowth that covers the cervical third and interproximal areas. It can be localized or generalized.
Grade 3	Severe gingival overgrowth that covers the cervical two thirds and interproximal areas. It can be localized or generalized.



Picture 4.14. Grade 3 according to G.O. index by Nery et al. (Nery et al., 1995).

Examination of edentulous subjects included six areas to identify soft tissue overgrowth: One on each side of the maxillary posterior alveolar ridge; one on each side of the mandibular posterior ridge; and one on each of the maxillary and mandibular anterior regions. The scoring method was done as shown in Table 4.12.

Table 4.12. Classification of G.O. by Nery et al. in edentulous patients (Nery et al., 1995)

Grade	Description
Grade 0	No overgrowth at any location
Grade 1	One or two area of soft tissue overgrowth
Grade 2	Three or four areas of soft tissue overgrowth
Grade 3	Five or six areas of soft tissue overgrowth (generalized)

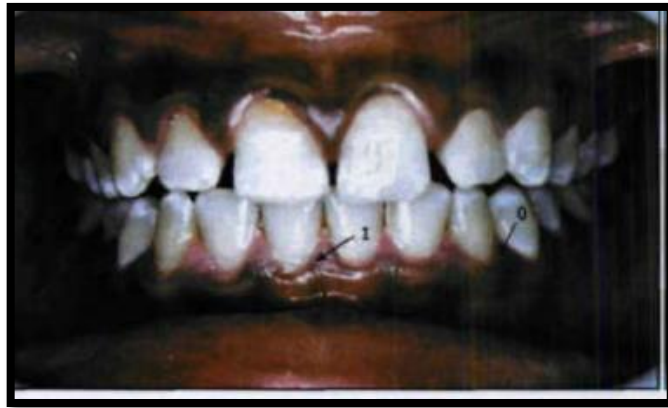4.4.1.16. Prasad et al. index

In 1998, Prasad et al. (Prasad et al., 1998) studied phenytoin-induced G.O. in epileptic children in a six-months evaluation. These children were evaluated at baseline and at three monthly intervals for six-months period. A gingival sulcus deeper than 4 mm indicated the formation of a pseudopocket i.e. overgrowth of the gingiva in the vertical dimension. The mesiodistal dimension of G.O., when it occurred during

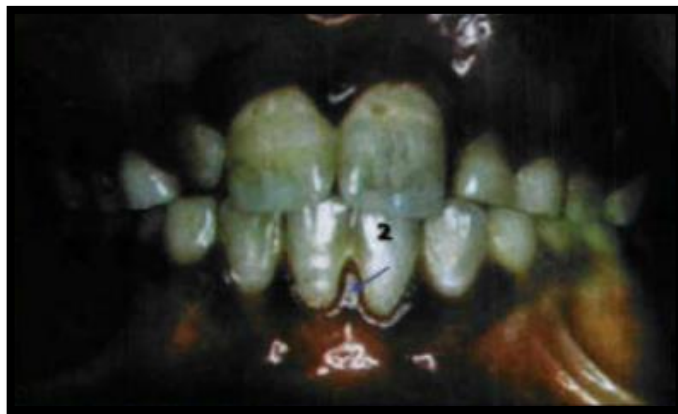
the follow-up period of six months, was measured according to the modified version of Harris and Ewalt index. The gingival units used to record mesiodistal dimension of G.O. and pocket depths were the same since the two methods measured different aspects of the same parameter (G.O.). Four gingival units for each firm and completely erupted tooth (except 2nd and 3rd permanent molars if present) were chosen: facial, proximo-facial, lingual and proximo-lingual. The proximal units chosen for recording sulcus depth in the left upper and lower quadrants were mesio-facial and mesio-lingual while those for use in the right upper and lower quadrants were disto-facial and disto-lingual. The classification of G.O. according to Prasad et al. (modified Harris and Ewalt) is described as it is shown in Table 4.13 and divided into grade 0 and 1 (Picture 4.15), grade 2 (Picture 4.16), grade 3 (Picture 4.17) and grade 4 and 5 (Picture 4.18). The gingival units used in this index are shown in Figure (4.2).

Table 4.13. Classification of G.O by Prasad et al. (Modified Harris and Ewalt) (Prasad et al., 1998)

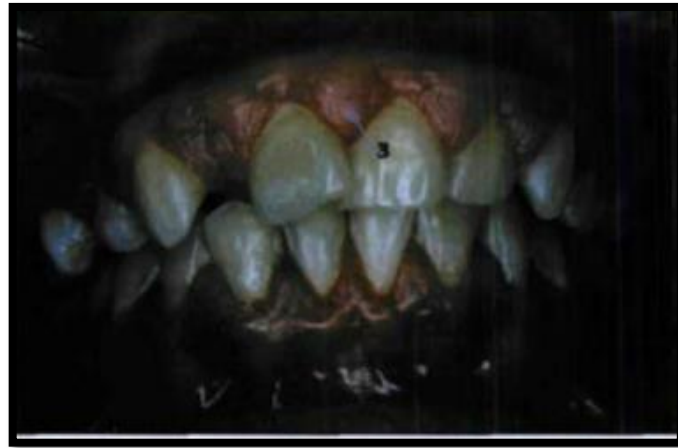Score	Condition
Grade 0	No clinical signs of hyperplasia
Grade 1	Minimal hyperplasia: <ul style="list-style-type: none"> • Impression of increase in density • With/without accentuation of stippling • Firm appearance • No distinct increase in size of inter-dental papilla • Loss of corrugated appearance • And/or loss of knife-edge appearance of gingival margins
Grade 2	Moderate hyperplasia: <ul style="list-style-type: none"> • Increase in size of the interdental papilla such that the papilla does not extend beyond the facio-proximal and linguo-proximal line angles of teeth on either • Noticeably rolled gingival margins
Grade 3	Marked hyperplasia: <ul style="list-style-type: none"> • Encroachment < 50% of the anatomic crown either inciso-gingivally or mesio-distally or either side.
Grade 4	Severe hyperplasia: <ul style="list-style-type: none"> • Encroachment of the gingival tissues to cover more than > 50% of the anatomic crown inciso-gingivally or mesio-distally on either side
Grade 5	Interference with function



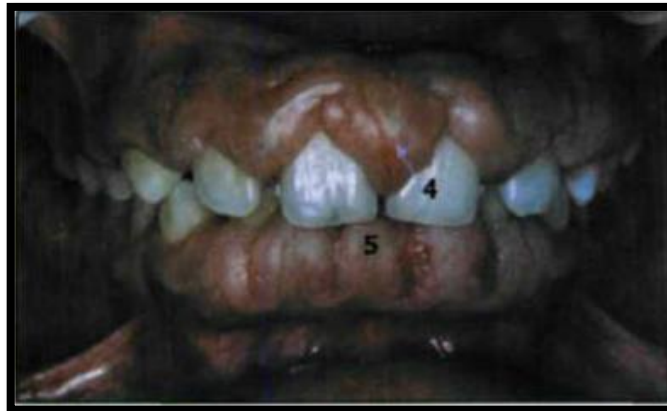Picture 4.15. Grade 0 and 1 G.O. according to modified Harris and Ewalt index (Prasad et al., 1998)



Picture 4.16. Grade 2 G.O. according to modified Harris and Ewalt index (Prasad et al., 1998)



Picture 4.17. Grade 3 G.O. according to modified Harris and Ewalt index (Prasad et al., 1998)



Picture 4.18. Grade 4 and 5 G.O. according to modified Harris and Ewalt index (Prasad et al., 1998)

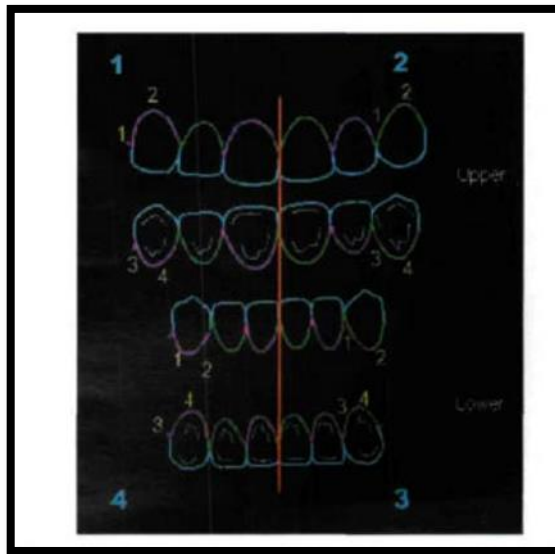


Figure 4.2. Gingival units for recording probing depth of gingival sulcus and G.O. according to modified Harris and Ewalt index (Prasad et al., 1998).

4.4.1.17. Inglés et al. index

In 1999, Inglés et al. (Inglés et al., 1999) presented a new clinical index for classifying drug-induced G.O. The index can be applied readily to documentation of the patient's periodontal status during supportive therapy as a record of the progression of G.O. This index was evaluated on 9 renal transplant patients who were under CsA and nifedipine or CsA treatment alone. One score was given to the buccal papillae and another to the lingual papillae. Calibration examinations were conducted. Two examiners scored each patient twice for inter-examiner agreement. The percentage of agreement for this G.O. index ranged from 86.7% to 92.9% on the buccal aspect and from 87.5% to 96.6% on the lingual aspect. Calibration examinations were done before and after surgical treatment. Scores 0, 1, and 2 corresponded to evaluations in the post-operative period after complete-mouth gingivectomy. On the other hand, scores 3 and 4 coincided with assessments performed at the initial presentation of the patient at the pretreatment period. The criteria of this index is described as the following:

- **Grade 0:**

- No overgrowth; firm adaptation of the attached gingiva on the underlying alveolar bone.
- There is slight stippling; there is no granular appearance or a slightly granular appearance.
- A knife-edged papilla is present toward the occlusal surface.
- There is no increase in density or size of the gingiva as it is shown in Figure 4.3.

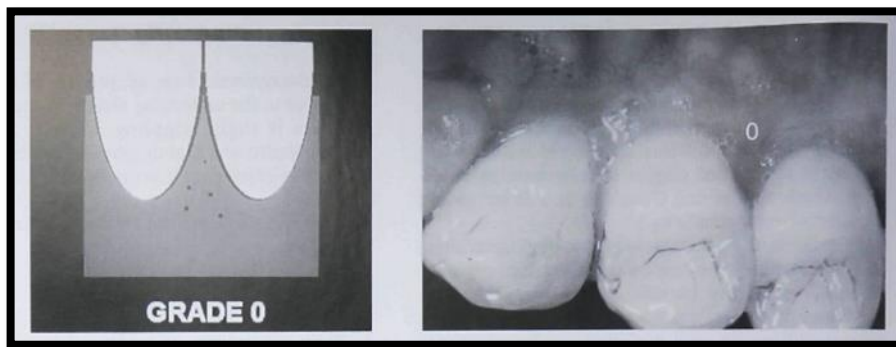


Figure 4.3. Grade 0 G.O. according to Inglés et al. (Inglés et al., 1999)

- **Grade 1:**

- Early overgrowth, as evidenced by an increase in density of the gingiva with marked stippling and granular appearance as it is described in Figure 4.4.
- The tip of the papillae is rounded.
- The probing depth is less than or equal to 3 mm.




Figure 4.4. Grade 1 G.O. according to Inglés et al. (Inglés et al., 1999)

- **Grade 2:**

- Moderate G.O., manifested by an increase in the size of the papilla and/or rolled gingival margins as it is described in Figure 4.5.
- The contour of the gingival margin is still concave or straight.
- The G.O. has a buccolingual dimension of up to 2 mm, measured from the tip of the papilla outward.
- The probing depth is equal to or less than 6 mm.
- The papilla is somewhat retractable.




Figure 4.5. Grade 2 G.O. according to Inglés et al. (Inglés et al., 1999)

- **Grade 3:**

- Marked G.O., represented by encroachment of the gingiva on the clinical crowns as it is described in Figure 4.6.
- The contour of the gingiva is convex rather than concave.
- The G.O. has a buccolingual dimension of approximately 3 mm or more, measured from the tip of the papilla outward.
- The probing depth is greater than 6 mm.
- The papilla is clearly retractable.



Figure 4.6. Grade 3 G.O. according to Inglés et al. (Inglés et al., 1999)

- **Grade 4:**

- Severe G.O., characterized by a profound thickening of the gingiva.
- A large percentage of the clinical crowns is covered as it is described in Figure 4.7.
- Same as for grade 3: the papilla is retractable, the probing depth is greater than 6mm, and the buccolingual dimension is approximately 3 mm.

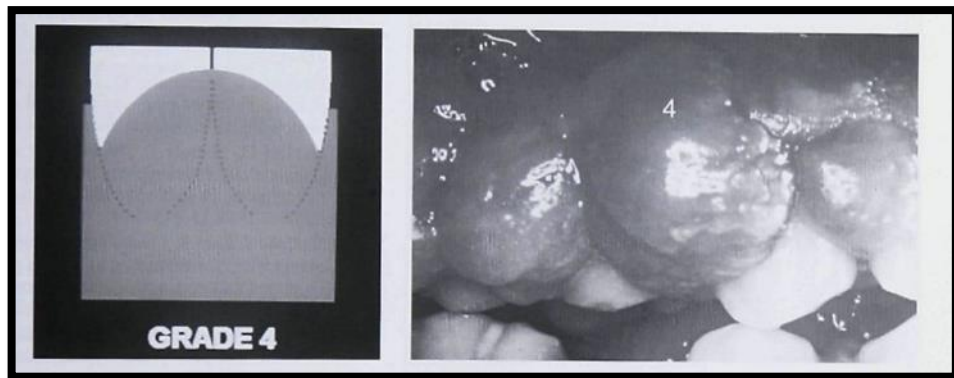


Figure 4.7. Grade 4 G.O. according to Inglés et al. (Inglés et al., 1999)

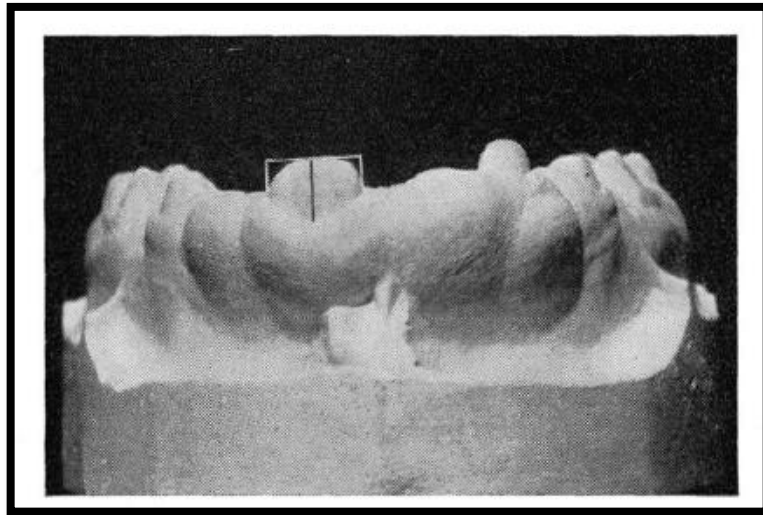
4.4.2. Plaster model measurements

4.4.2.1. Ingle et al. index

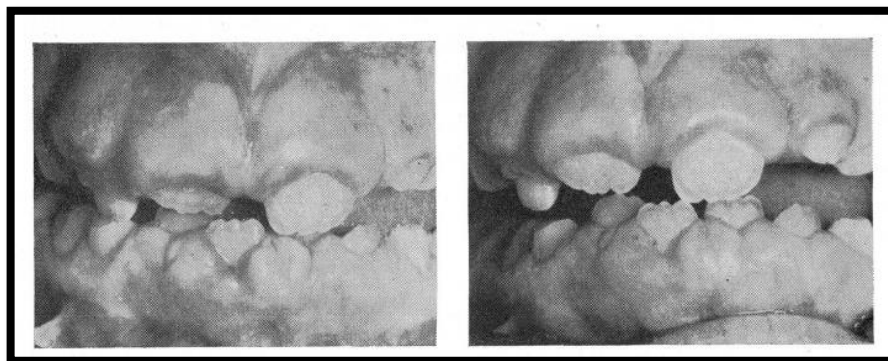
In 1959, Ingle et al. (Ingle et al., 1959) had a study on epileptic patients using diphenylhydantoin to examine an antihistamine's, chlorprophenpyridamine maleate, efficiency in reducing gingival hyperplasia which is one of the major side effects of this antiepileptic drug. Study models were poured after taking alginate impressions for both maxilla and mandible. In addition, color photographs of the anterior teeth in centric occlusion were taken. The same equipment had been used for all patients' photographs with film at a standard 5.5 inch focal length, using a uniform lighting system.

Evaluation of study models were done by measuring the distances between the height of tissue and the incisal edge of all six anterior teeth on the plaster models as the following: incisal edge to distal and mesial papilla, and to marginal gingiva as it is shown in Picture 4.20. The same method was used by totaling these measurements and averaging the total for each patient to be compared with subsequent models taken during recall sessions for each patient. The increase in crown length of the 30 and 60 day models is visible and apparent if shrinkage of the gingival hyperplasia occurred. Over-all dimensional changes in millimeters were compiled and were converted to percentages and charted as to decrease or increase in the level of the tissue.

Evaluation of the photographs by projecting the initial and subsequent series of Kodachrome transparencies of every patient side by side using two projectors of 35 mm. The examiners classified the patients according to changes in color, stippling, tissue's level and tone by careful comparison between the "before" and "after" slides as shown in Picture 4.21.



Picture 4.20. Study model, showing the three points of measurements according to Ingle et al. (Ingle et al., 1959)



Picture 4.21. Example of intermittent tooth eruption in 60 days according to Ingle et al. (Ingle et al., 1959).

4.4.2.2. Seymour et al. index

In 1985, Seymour et al. (Seymour et al., 1985) studied the effects of phenytoin and sodium valproate on the periodontal health adult epileptic patients. To assess the G.O. grade, gingival thickness was classified as shown in Table 4.14 and Figure 4.8. On the other hand, the vertical component of G.O. index by Seymour et al. is described as shown in Figure 4.9.

Table 4.14. Classification of G.O. horizontally by Seymour et al. (Seymour et al., 1985)

Gingival thickening	Description
Grade 0	Normal thickening of the gingiva
Grade 1	Thickening from the normal up to 2 mm
Grade 2	Thickening from the normal greater than 2 mm

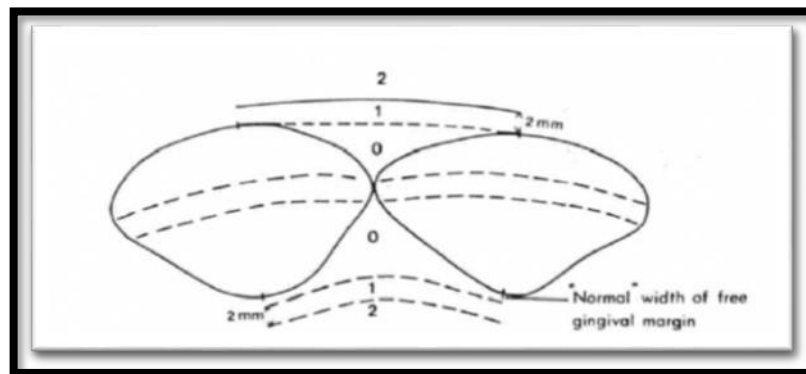


Figure 4.8. Horizontal component (thickening) to assess G.O. by Seymour et al. index (Seymour et al., 1985)

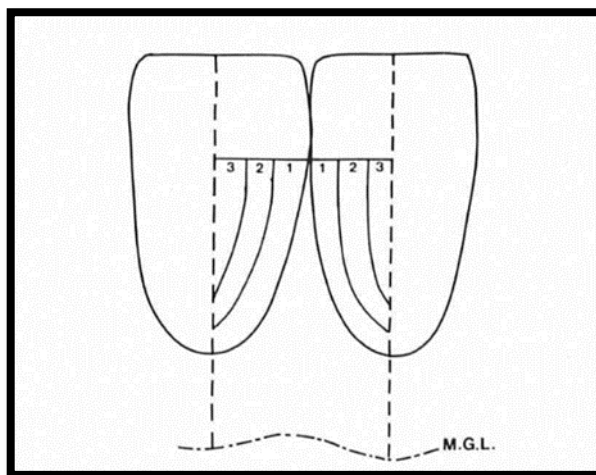


Figure 4.9. Vertical component (encroachment) to assess G.O. by Seymour et al. index (Seymour et al., 1985)

Two scores (gingival thickening and gingival encroachment) were added giving an overgrowth score for each gingival unit.

4.4.2.3. Dahllöf et al index

In 1986, Dahllöf et al. (Dahllöf et al., 1986) studied the effect of a plaque control program on the development of phenytoin-induced G.O. in 16 epileptic children during a 2-year longitudinal study. In order to grade G.O., the thickness of marginal gingiva bucco-lingually was measured on stone casts. The measurements were done in two regions (incisor and first molar) in both maxilla and mandible. The bucco-lingual thickness of the marginal gingiva was measured from the buccal surface of the tooth to the most prominent area of the marginal gingiva. The most cervical point on the buccal surface of the tooth was used as a reference point.

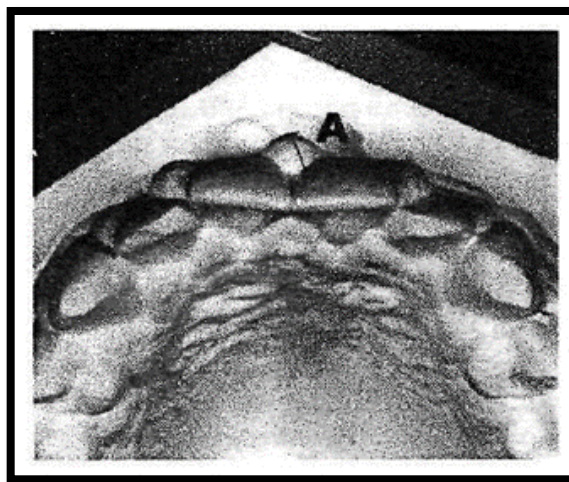
4.4.2.4. King et al. index

In 1993, King et al. (King et al., 1993) studied G.O. in renal allograft recipients receiving CsA and calcium antagonists. To assess G.O.'s severity, upper and lower dental arch alginate impressions were taken during the clinical examination and poured up in dental plaster models. G.O. was determined from the study models of the 12 anterior teeth, using the hyperplastic index (H.I.) that is comprised of two components that independently measures the horizontal and vertical G.O. extensions. The upper and lower dental plaster models were divided into five gingival units (anteriorly), according to the method developed by Seymour et al. (Seymour et al., 1985). Each gingival unit was measured (buccally/lingually) from the midpoint of the tooth to the midpoint of the adjacent tooth, extending from the 13 to 23 in the maxilla and from 33 to 43 in the mandible. A premolar was substituted when one of the previously mentioned required teeth was missing. As 2 individuals were unable to bear an alginate impression, the measurement of G.O. using H.I. was done at the chairside.

The horizontal component of H.I. which was developed by Seymour et al. (Seymour et al., 1985) is described as it is shown in Table 4.15. The horizontal component of H.I. measured the degree of gingival thickening on both the labial and lingual aspects in a labio-lingual direction (Picture 4.22).

Table 4.15. The H.I of horizontal component or labio-lingual direction by King et al. (King et al., 1993)

Gingival thickening	Description
Grade 0	Normal thickening of the gingiva
Grade 1	Thickening from the normal up to 2 mm
Grade 2	Thickening from the normal greater than 2 mm

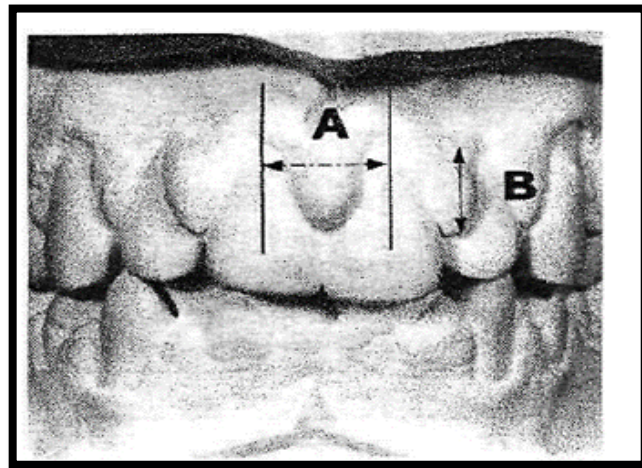


Picture 4.22. Occlusal view of the upper anterior section of the study model. (A) for a gingival unit (King et al., 1993).

On the other hand, the vertical component of the H.I. focuses on measuring the degree of G.O. in an apico-coronal direction (vertical) for a gingival unit and was graded by means of a 4-point interval scale as shown in Table 4.16 and Picture 4.23.

Table 4.16. The HI of vertical component or apico-coronal direction by King et al. (King et al., 1993)

Vertical G.O.	Description
Grade 0	No gingival hyperplasia
Grade 1	Mild hyperplasia (blunting of gingival margin)
Grade 2	Moderate hyperplasia (less than ½ of crown length)
Grade 3	Severe hyperplasia (more than ½ of crown length)



Picture 4.23. Study model shows buccal surfaces of the upper and lower anterior teeth. (A) Gingival unit. (B) Gingival enlargement in an apico-coronal direction (King et al., 1993).

Both the horizontal and vertical components of the H.I. were added to give a hyperplastic measuring for each gingival unit. The maximum measuring score could be obtained using this H.I. for each gingival unit is 5. Since 20 gingival units were examined using this index, the degree of G.O. in the upper and lower anterior teeth was expressed as a percentage (Seymour et al., 1985).

Individuals were also divided into subgroups depending on their H.I. as responders and non-responders. Subjects with a H.I. equal or less than 30% were regarded as non-responders ($H.I. \leq 30\%$). Other subjects who scored a H.I. greater than

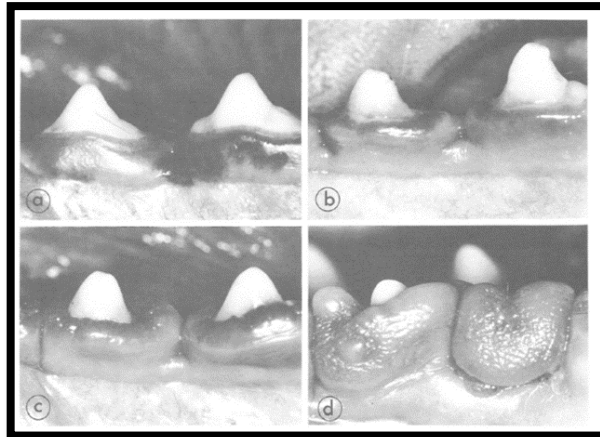
30% were regarded as responders (H.I.>30%). This manner of subdividing the subjects into responders and non-responders groups was similar to that suggested by Thomason and Seymour 1992, and Seymour and Smith 1991.

4.4.3. Intra-oral photographs measurements

4.4.3.1. Heijl and Sundin index

In 1989, Heijl and Sundin (Heijl and Sundin, 1989) studied the development of G.O. in dogs under nitrendipine, which is considered as a new antihypertensive dihydropyridine at that time. Color photographs were used to determine signs of G.O. Gingival size was compared between the different time points and the conditions predominant at the initial examination for each dog as shown in Picture 4.24. Gingival changes in size were assessed according to a Gingival Size Index (G.S.I.), in which gingival changes in the mesial, buccal, and distal surfaces for each one of the teeth were evaluated:

- Grade 0: No change in size from the initial examination
- Grade 1: Indication of a small but clinically evident increase in size
- Grade 2: Marked increase
- Grade 3: Extensive increase with the gingival tissues covering the corresponding aspect of tooth surface and/or with deep clefts into the enlarged gingiva



Picture 4.24. Classification of G.O. by Heijl and Sundin. (A) Score index 0; (B) Score index 1; (C) Score index 2; (D) Score index 3 (Heijl and Sundin, 1989).

4.4.3.2. O'valle et al. index

In 1995, O'valle et al. (O'valle et al., 1995) developed a new method to evaluate the degree of G.O. by using a quantitative method with digital image analysis. This index characterizes the relation between the attached and free gingival margin and the vestibular surface of the 8 anterior teeth. Subjects who received any other drugs which might affect the gingival status were excluded from the study and only patients who have at least six of the eight most anterior teeth. The G.O. index of this study was classified on the basis of the criteria of Angelopoulos and Goaz (Angelopoulos and Goaz, 1972) (Table 4.17).

Table 4.17. Classification of gingival overgrowth by O’valle et al. (O’valle et al., 1995)

Grade	Description
Grade 0	No enlargement
Grade 1	Mild enlargement on the marginal gingiva and there is encroachment on third of the tooth
Grade 2	Moderate enlargement
Grade 3	Severe enlargement and the encroachment covers big part of the tooth

4.4.3.3. Ellis et al. index

In 2001, Ellis et al. (Ellis et al., 2001) invented a photographic scoring index of G.O. The aim of the study was to describe an index to assess G.O. which is suitable for use in large-scale populations. In the clinical scoring method, authors ascribed patients a general whole-mouth score of between 0 and 3 (Table 4.18) (Figure 4.10).

Photographic technique:

Two operators have taken all slides using Kodak Ektachrome Elite 200 ASA. Spandex plastic retractors were used to retract patients’ cheeks. Pentax K 1000 camera was used with Tamron Sp 90 mm 1:25 lens and Cobra Macro Ring flash, and an F-stop of 11. The lens was opened up fully. Focusing was achieved by modifying the distance between the camera and the object i.e. anterior teeth. Focus was achieved at an approximate film-object distance of 40 cm. An accurate and completely reproducible photographic technique was achieved. Duplicate slides were taken of each subject. Slides were then processed, mounted and marked with the subject’s study number.

Table 4.18. Classification of G.O. by Ellis et al. (Ellis et al., 2001)

Grade	Description
Grade 0	No encroachment of interdental papilla onto tooth surface
Grade 1	Mild encroachment of interdental papilla, producing a blunted appearance to papilla tip
Grade 2	Moderate encroachment, involving lateral spread of papilla across buccal tooth surface of less than quarter tooth width
Grade 3	Marked encroachment of interdental papilla, i.e., more than one quarter tooth width. Loss of normal papilla form

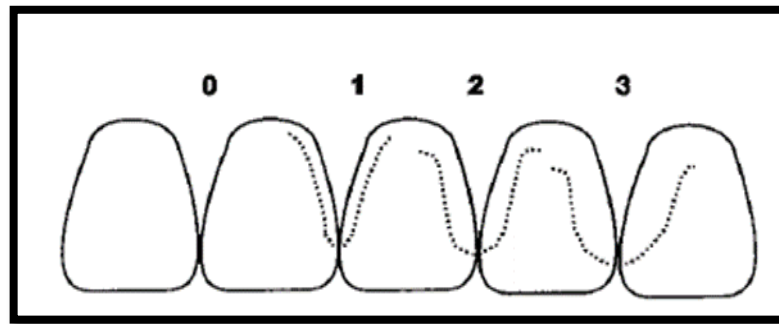


Figure 4.10. Criteria to assess G.O. according to Ellis et al. index (Ellis et al., 2001).

5. MATERIALS AND METHODS

This study was approved by the Ethical Committee of Clinical Research, Faculty of Dentistry, Marmara University on 06/06/2017 with number 2017-113. Records of patients who were referred to the Department of Periodontology, Faculty of Dentistry, Marmara University, with generalized G.O. due to inflammatory, drug-induced, pubertal or hereditary factors were utilized. Patients who applied to the clinics, and had records including plaster models poured out from alginate impressions for both maxilla and mandible, and intra-oral photographs which were taken at the patients' first visit to the clinics.

All the procedures in terms of collecting the diagnostic data were explained to the patients and each individual signed a consent form as they accepted participating in the study voluntarily.

5.1. Patient Selection

Inclusion criteria:

- Dental records of patients having inflammatory, drug-induced, pubertal or hereditary G.O. on at least 12 anterior teeth (Between 31 and 32 in the maxilla, and between 33 and 34 in the mandible).
- Presence of plaster models (maxilla/mandible) of pre-treatment phase.
- Presence of intra-oral photographs of pre-treatment phase.

Exclusion criteria:

- Dental records of patients having G.O., but missing one or more of their 12 anterior teeth (between 31 and 32 in the maxilla, and between 33 and 34 in the mandible).
- Patients having G.O. with distorted plaster models such like bubbles or unclear features.
- Patients having G.O. with blurry photographs.

5.2. Study Design

Out of 60 patients who were reviewed for history of G.O. condition, records of 30 patients (15 males and 15 females), who matched with the enrollment criteria, were chosen to participate in the study. Three trained examiners (S.A., L.K., H.O.O.) measured the degree of G.O. of each patient twice according to the criteria of four different indices. An interval of two weeks was between the first and the second measurement.

5.3. Gingival Overgrowth Measurements

Four indices have been selected for measuring G.O. in this study.

5.3.1. Modified Harris and Ewalt index

Plaster models were used to measure the modified version of Harris and Ewalt index in the order of facial, proximo-facial, lingual and proximo-lingual. The criteria of assessing G.O. according to the modified Harris and Ewalt index is described in Table 5.1.

Table 5.1. Classification of G.O according to the modified Harris and Ewalt index (Prasad et al., 1998).

Score	Condition
Grade 0	No clinical signs of hyperplasia
Grade 1	Minimal hyperplasia: <ul style="list-style-type: none"> • Impression of increase in density • With/without accentuation of stippling • Firm appearance • No distinct increase in size of inter-dental papilla • Loss of corrugated appearance • And/or loss of knife-edge appearance of gingival margins
Grade 2	Moderate hyperplasia: <ul style="list-style-type: none"> • Increase in size of the interdental papilla such that the papilla does not extend beyond the facio-proximal and linguo-proximal line angles of teeth on either Noticeably rolled gingival margins
Grade 3	Marked hyperplasia: <ul style="list-style-type: none"> • Encroachment < 50% of the anatomic crown either inciso-gingivally or mesio-distally or either side.
Grade 4	Severe hyperplasia: <p>Encroachment of the gingival tissues to cover more than > 50% of the anatomic crown inciso-gingivally or mesio-distally on either side</p>
Grade 5	Interference with function

5.3.2. Seymour et al. index

In order to assess G.O.'s grade according to Seymour et al. index (Seymour et al., 1985), the upper and lower anterior segments were divided into five gingival units for each maxilla and mandible, and to both buccal and palatal/lingual sides.

This index is divided into horizontal and vertical components which makes it a three-dimensional index. The horizontal component examines the degree of gingival thickness regarding both labial and lingual aspects as shown in Table 5.2.

Table 5.2. Classification of G.O. horizontally according to the Seymour et al. index (Seymour et al., 1985)

Gingival thickening	Description
Grade 0	Normal thickening of the gingiva
Grade 1	Thickening from the normal up to 2 mm
Grade 2	Thickening from the normal greater than 2 mm

The vertical component examines the encroachment extent of the gingival tissues onto the adjacent clinical crowns, and graded on both labial and lingual surfaces. The higher score was given if there is any discrepancy between encroachment on two adjacent surfaces in one unit. Figure 5.1. demonstrates the vertical component of Seymour et al. index which describes the encroachment grade.

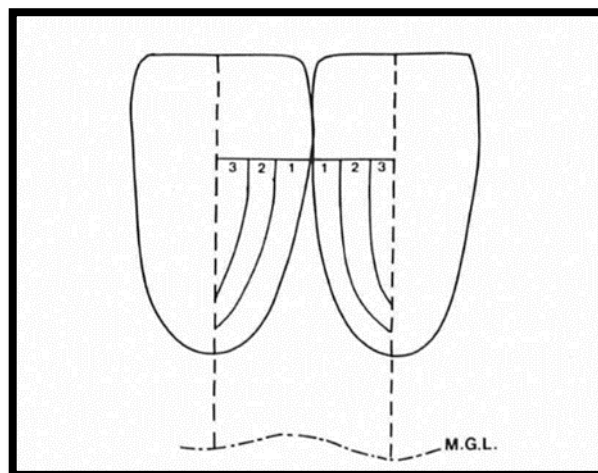


Figure 5.1. Vertical component of the Seymour et al. index (Seymour et al., 1985).

Two scores describing gingival thickening and gingival encroachment were added to obtain one score for each gingival unit. The maximum score attainable using this method is 5 (2 horizontally and 3 vertically).

5.3.3. Hyperplastic index by King et al.

The H.I. described by King et al. (King et al., 1992) is divided into two components that independently measures the horizontal and vertical G.O. extensions. Anterior regions of each upper and lower plaster models were divided into five gingival units according to the method developed by Seymour et al. (Seymour et al., 1985) and extending from 13 to 23 in the maxilla and from 33 to 43 in the mandible.

The horizontal component of the H.I., which was developed by Seymour et al. (Seymour et al., 1985), measures the degree of gingival thickening on both the labial and lingual aspects in a labio-lingual direction for a gingival unit as shown in Table 5.3.

Table 5.3. The horizontal component of H.I. index by King et al. (King et al., 1992)

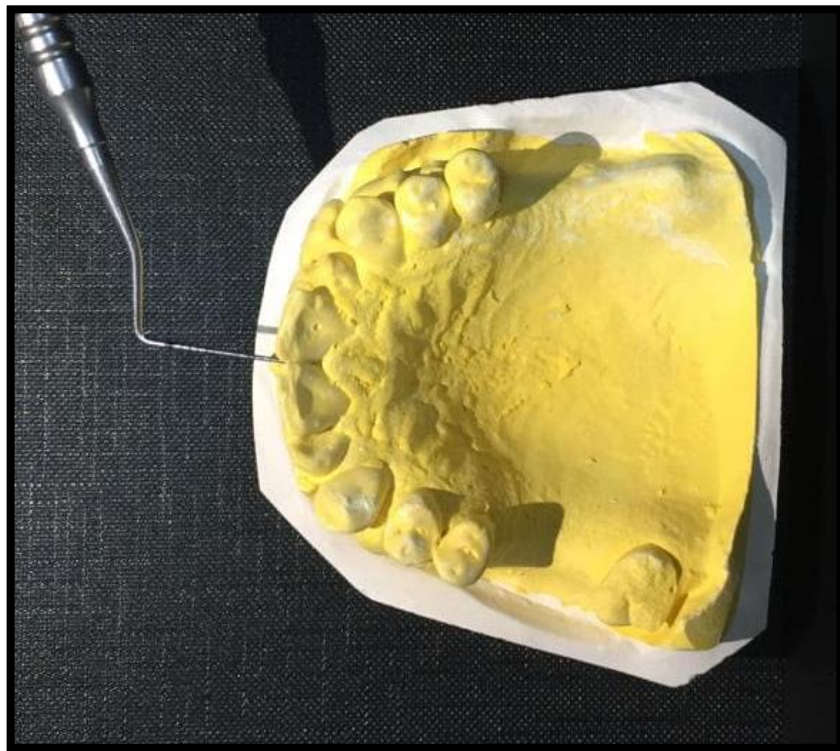Gingival thickening	Description
Grade 0	Normal thickening of the gingiva
Grade 1	Thickening from the normal up to 2 mm
Grade 2	Thickening from the normal greater than 2 mm

The vertical component of the H.I. focuses on measuring the degree of G.O. in an apico-coronal direction for a gingival unit and was graded by means of a 4-point interval scale as shown in Table 5.4.

Table 5.4. The vertical component of H.I. index by King et al. (King et al., 1992)

Vertical G.O.	Description
Grade 0	No gingival hyperplasia
Grade 1	Mild hyperplasia (blunting of gingival margin)
Grade 2	Moderate hyperplasia (less than ½ of crown length)
Grade 3	Severe hyperplasia (more than ½ of crown length)

In order to assess the horizontal component of King et al. index, a PCPUNC-15 periodontal probe was used by measuring the labio-lingual dimension of the interdental papillae on plaster models as presented in Picture 5.1.



Picture 5.1. Assessing the horizontal aspect by H.I. of King et al.

5.3.4. Ellis et al. index

Intra-oral photographs were taken for each patient including the buccal, right, left, upper occlusal and lower occlusal aspects. Spandex plastic retractors were used to retract patients' cheeks. Canon EOS 60D camera was used with Tamron Sp 100 mm 1:25 lens and Cobra Macro Ring flash, and an F-stop of 11. The lens was opened up fully. Focus was achieved at an approximate film-object distance of 40 cm and by modifying the distance between anterior teeth and the camera. All intra-oral photographs (Picture 5.2) were organized and marked with the patient's study number.

According to the method described by Ellis et al., the degree of G.O. is given to each anterior papilla on the buccal aspect. A total of 10 gingival units was measured buccally from the midpoint of the tooth to the midpoint of the adjacent tooth between 13 to 23, and 33 to 43.

Table 5.5. and Figure 5.2. show the division of each grade to evaluate G.O. focused on the encroachment according to the method described by Ellis et al. (Ellis et al., 2001).

Table 5.5. Classification of G.O. according to Ellis et al. index (Ellis et al., 2001)

Grade	Description
Grade 0	No encroachment of interdental papilla onto tooth surface
Grade 1	Mild encroachment of interdental papilla, producing a blunted appearance to papilla tip
Grade 2	Moderate encroachment, involving lateral spread of papilla across buccal tooth surface of less than quarter tooth width
Grade 3	Marked encroachment of interdental papilla, i.e., more than one quarter tooth width. Loss of normal papilla form

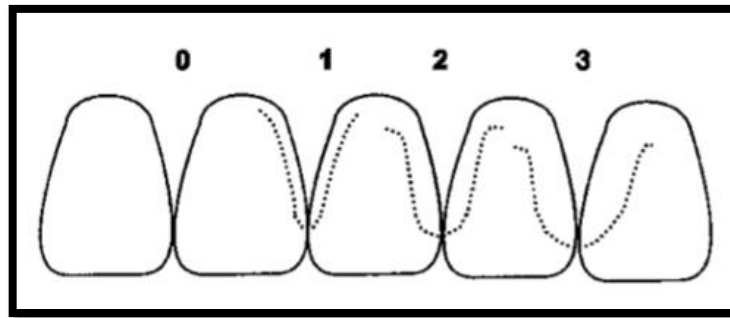
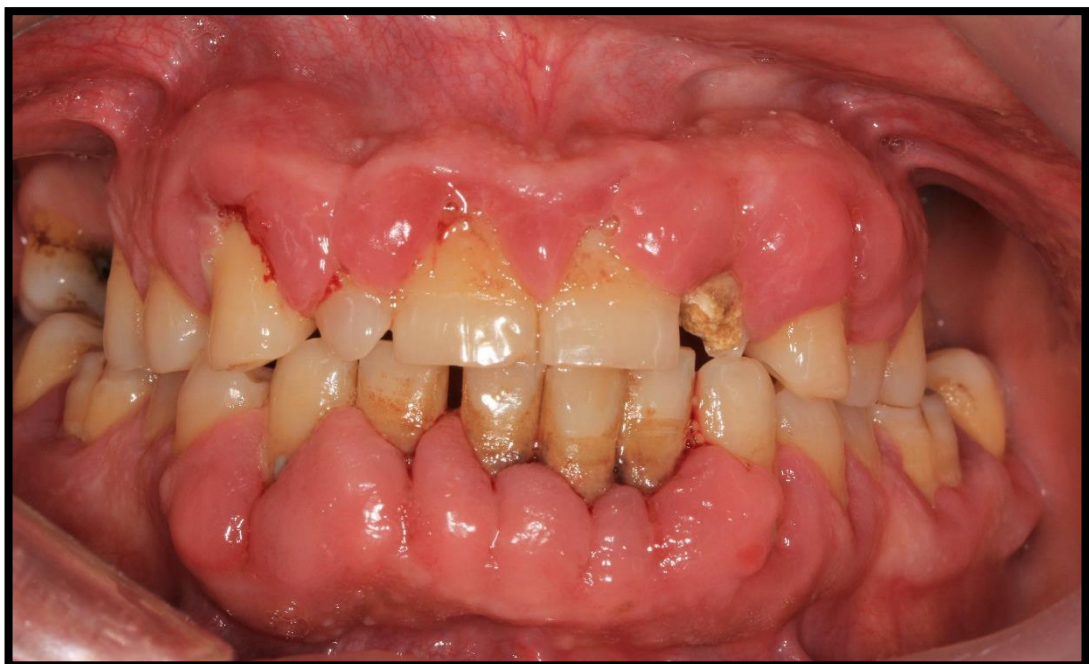

Figure 5.2. The degree of G.O. according to Ellis et al. index (Ellis et al., 2001).



Picture 5.2. Intra-oral photograph of the buccal aspect of a drug-induced G.O. patient

5.4. Statistical Analysis

The measurements from 30 different patients, measured twice by three different examiners were compared. Concordance of intra-examiner and inter-examiner analysis of the recorded measurements was carried out for each index using the weighted Kappa index with a confidence interval (95%) using SPSS program. If p value $<0,05$, It means that the agreement is statistically significant, and there is (poor/fair/moderate/ good/very good)agreement.

Conventional interpretation of the strength of agreement for Kappa values was adopted (Altman, 1991) as follows: ($< 0,20$ = poor concordance; $0,21-0,40$ = fair concordance; $0,41-0,60$ = moderate concordance; $0,61-0,80$ = good concordance; $0,81-1,00$ = very good concordance. Negative results were interpreted as $0,00$.

5.5.Calibration

The three examiners (Examiner-1, Examiner-2, and Examiner-3) measured the degree of G.O. on 3 patients using the horizontal component of Seymour et al. index (Seymour et al., 1985) twice with 24 hours interval between the two trials. The three examiners showed very good agreement with total kappa values of $0,830$ and $0,886$ and $0,833$ for Examiner-1, Examiner-2, and Examiner-3, respectively.

6. RESULTS

Sixty patients with G.O. who applied to the clinics of Department of Periodontology, Faculty of Dentistry, Marmara University between September 2018 and February 2019 were evaluated for examining the reliability of four G.O. indices. A total of 30 patients who met the inclusion criteria of our study and voluntarily agreed to participate in the study were included.

6.1. Demographic Data

Demographic data of all participants are shown in Table 6.1. The mean age of 30 patients between the ages of 13-70 years participated in the study was $44,47 \pm 17,14$. According to gender, 50% of the study population was female (n = 15, mean age = $44,46 \pm 17,70$) and the other half was male (n = 15, mean age = $43,80 \pm 16,57$).

The majority of included patients were drug-induced G.O. subjects (n=18, 60%), followed by 9 patients with inflammatory G.O. (30%), 2 patients with pubertal G.O. (6,7%), and one patient with hereditary G.O. (3,3%).

Table 6.1. Demographic data of all participants

	Number of individuals (n)	Age (years) (Mean\pmSd)	Gender (Female/Male) n (%)	Type of G.O. (Drug-induced Inflammatory Pubertal Hereditary) n/%
All Patients	30	44,47 \pm 17,14	15/15 (50/50)	18/60,0 9/30,0 2/6,7 1/3,3

Sd: Standard deviation

6.2. Gingival Overgrowth Indices

Plaster models and intraoral photographs of 30 patients who have had generalized G.O. were used to measure four G.O. indices including modified Harris and Ewalt index (Prasad et al., 1998), Seymour et al. index (Seymour et al., 1985), King et al. index (King et al., 1993) and Ellis et al. index (Ellis et al., 2001) by 3 examiners (Examiner-1, Examiner-2, Examiner-3) twice.

6.2.1. Intra-examiner reliability

6.2.1.1. Modified Harris and Ewalt index

Each gingival unit's measurement value according to modified Harris and Ewalt index (Prasad et al., 1998) was compared between the first and second time evaluations. The intra-examiner's results of Examiner-1, Examiner-2 and Examiner-3 using modified Harris and Ewalt index are shown in Tables 6.2, 6.3 and 6.4, respectively.

Table 6.2. Reliability of Examiner-1 measuring modified Harris and Ewalt index

Site	N	Kappa	Std. Error	P*	Site	N	Kappa	Std. Error	P*
DV16	20	0,828	0,114	0,000	DV46	17	0,840	0,102	0,000
V16	20	0,818	0,122	0,000	V46	17	0,667	0,144	0,000
DV15	24	0,814	0,102	0,000	DV45	25	0,650	0,117	0,000
V15	24	0,821	0,122	0,000	V45	25	0,801	0,108	0,000
DV14	22	0,745	0,114	0,000	DV44	29	0,942	0,057	0,000
V14	22	0,770	0,118	0,000	V44	29	0,752	0,134	0,000
DV13	30	0,818	0,083	0,000	DV43	30	0,693	0,109	0,000
V13	30	0,803	0,101	0,000	V43	30	0,705	0,118	0,000
DV12	30	0,703	0,111	0,000	DV42	30	0,842	0,084	0,000
V12	30	0,786	0,095	0,000	V42	30	0,814	0,103	0,000
DV11	30	0,540	0,143	0,000	DV41	30	0,844	0,086	0,000
V11	30	0,871	0,088	0,000	V41	30	0,675	0,128	0,000
MV21	30	0,755	0,113	0,000	MV31	30	0,904	0,065	0,000
V21	30	0,792	0,115	0,000	V31	30	0,664	0,121	0,000
MV22	30	0,604	0,123	0,000	MV32	30	0,670	0,108	0,000
V22	30	0,851	0,101	0,000	V32	30	0,759	0,114	0,000
MV23	30	0,627	0,125	0,000	MV33	30	0,739	0,107	0,000
V23	30	0,824	0,097	0,000	V33	30	0,885	0,079	0,000
MV24	23	0,702	0,127	0,000	MV34	28	0,677	0,123	0,000
V24	23	0,693	0,144	0,000	V34	28	0,752	0,133	0,000
MV25	21	0,855	0,096	0,000	MV35	26	0,736	0,119	0,000
V25	21	0,834	0,106	0,000	V35	26	0,644	0,164	0,000
MV26	21	0,703	0,131	0,000	MV36	17	0,648	0,183	0,007
V26	21	0,800	0,126	0,000	V36	17	0,655	0,184	0,001
DO16	20	0,708	0,125	0,000	DO46	17	0,642	0,149	0,000
O16	20	0,850	0,099	0,000	O46	17	0,588	0,171	0,000
DO15	24	0,755	0,108	0,000	DO45	25	0,792	0,107	0,000
O15	24	0,863	0,088	0,000	O45	25	0,735	0,121	0,000
DO14	22	0,725	0,119	0,000	DO44	29	0,638	0,118	0,000
O14	22	0,538	0,136	0,000	O44	29	0,625	0,105	0,000
DO13	30	0,657	0,108	0,000	DO43	30	0,793	0,095	0,000
O13	30	0,758	0,099	0,000	O43	30	0,595	0,131	0,000
DO12	30	0,752	0,099	0,000	DO42	30	0,712	0,116	0,000
O12	30	0,670	0,112	0,000	O42	30	0,778	0,104	0,000
DO11	30	0,590	0,125	0,000	DO41	30	0,723	0,115	0,000
O11	30	0,719	0,103	0,000	O41	30	0,835	0,089	0,000
MO21	30	0,768	0,093	0,000	MO31	30	0,766	0,111	0,000
O21	30	0,690	0,105	0,000	O31	30	0,687	0,114	0,000
MO22	30	0,804	0,091	0,000	MO32	30	0,776	0,105	0,000
O22	30	0,850	0,083	0,000	O32	30	0,837	0,085	0,000
MO23	30	0,662	0,115	0,000	MO33	30	0,793	0,097	0,000
O23	30	0,620	0,119	0,000	O33	30	0,889	0,076	0,000
MO24	23	0,730	0,116	0,000	MO34	28	0,898	0,070	0,000
O24	23	0,872	0,082	0,000	O34	28	0,849	0,082	0,000
MO25	21	0,620	0,150	0,000	MO35	26	0,755	0,112	0,000
O25	21	0,764	0,125	0,000	O35	26	0,809	0,103	0,000
MO26	21	0,613	0,150	0,000	MO36	17	1,000	0,000	0,000
O26	21	0,841	0,105	0,000	O36	17	0,611	0,188	0,006

DV: Disto-vestibule, V: Vestibule, MV: Mesio-vestibule, DO: Disto-oral, O: Oral, MO: Mesio-oral, *Kappa test, $p < 0.05$.

Examiner 1 showed intra-examiner total kappa value of 0,783 for 2532 sites with Std. Error of 0,010 (P=0,000).

Table 6.3. Reliability of Examiner-2 measuring modified Harris and Ewalt index

Site	N	Kappa	Std. Error	P*	Site	N	Kappa	Std. Error	P*
DV16	20	0,251	0,153	0,077	DV46	17	0,138	0,156	0,276
V16	20	0,336	0,131	0,007	V46	17	0,213	0,149	0,098
DV15	24	0,335	0,134	0,002	DV45	25	0,197	0,114	0,032
V15	24	0,107	0,131	0,314	V45	25	-0,030	0,136	0,769
DV14	22	0,212	0,147	0,067	DV44	29	0,143	0,114	0,131
V14	22	0,068	0,125	0,563	V44	29	0,253	0,129	0,028
DV13	30	0,481	0,114	0,000	DV43	30	0,290	0,122	0,005
V13	30	0,380	0,109	0,000	V43	30	0,277	0,104	0,011
DV12	30	0,288	0,123	0,009	DV42	30	0,517	0,110	0,000
V12	30	0,512	0,115	0,000	V42	30	0,459	0,109	0,000
DV11	30	0,198	0,126	0,066	DV41	30	0,318	0,116	0,007
V11	30	0,176	0,115	0,135	V41	30	0,332	0,108	0,001
MV21	30	0,301	0,123	0,003	MV31	30	0,298	0,118	0,008
V21	30	0,194	0,119	0,064	V31	30	0,259	0,106	0,005
MV22	30	0,474	0,109	0,000	MV32	30	0,303	0,115	0,003
V22	30	0,432	0,119	0,000	V32	30	0,136	0,107	0,184
MV23	30	0,369	0,120	0,000	MV33	30	0,390	0,125	0,001
V23	30	0,574	0,116	0,000	V33	30	0,171	0,120	0,112
MV24	23	0,356	0,128	0,001	MV34	28	0,538	0,121	0,000
V24	23	0,488	0,130	0,000	V34	28	0,278	0,122	0,008
MV25	21	0,548	0,136	0,000	MV35	26	0,392	0,118	0,000
V25	21	0,503	0,134	0,000	V35	26	0,218	0,124	0,028
MV26	21	0,342	0,140	0,005	MV36	17	0,089	0,138	0,461
V26	21	0,148	0,084	0,089	V36	17	0,261	0,133	0,018
DO16	20	0,091	0,129	0,426	DO46	17	0,130	0,127	0,301
O16	20	0,085	0,127	0,511	O46	17	0,337	0,151	0,021
DO15	24	0,242	0,124	0,021	DO45	25	0,286	0,136	0,013
O15	24	0,206	0,125	0,070	O45	25	0,382	0,138	0,001
DO14	22	0,125	0,146	0,280	DO44	29	0,269	0,120	0,005
O14	22	0,093	0,102	0,363	O44	29	0,356	0,117	0,000
DO13	30	0,360	0,106	0,000	DO43	30	0,204	0,113	0,036
O13	30	0,068	0,091	0,413	O43	30	0,154	0,103	0,122
DO12	30	0,216	0,129	0,038	DO42	30	0,221	0,134	0,034
O12	30	0,076	0,093	0,357	O42	30	0,114	0,116	0,278
DO11	30	0,346	0,119	0,002	DO41	30	0,402	0,114	0,000
O11	30	0,263	0,107	0,004	O41	30	0,123	0,112	0,237
MO21	30	0,310	0,107	0,001	MO31	30	0,440	0,121	0,000
O21	30	0,186	0,108	0,055	O31	30	0,320	0,133	0,001
MO22	30	0,297	0,112	0,005	MO32	30	0,406	0,116	0,000
O22	30	0,462	0,111	0,000	O32	30	0,231	0,125	0,035
MO23	30	0,346	0,121	0,000	MO33	30	0,192	0,113	0,055
O23	30	0,128	0,101	0,169	O33	30	0,356	0,130	0,000
MO24	23	0,386	0,124	0,000	MO34	28	0,415	0,125	0,000
O24	23	0,327	0,131	0,001	O34	28	0,497	0,118	0,000
MO25	21	0,371	0,139	0,001	MO35	26	0,257	0,130	0,015
O25	21	0,114	0,139	0,317	O35	26	0,231	0,130	0,029
MO26	21	0,170	0,105	0,127	MO36	17	0,457	0,147	0,001
O26	21	0,456	0,143	0,001	O36	17	0,138	0,121	0,273

DV: Disto-vestibule, V: Vestibule, MV: Mesio-vestibule, DO: Disto-oral, O: Oral, MO: Mesio-oral, *Kappa test, $p < 0.05$.

Examiner-2 showed intra-examiner total kappa value of 0,428 for 2532 sites with Std. Error of 0,013 (P=0,000).

Table 6.4. Reliability of Examiner-3 measuring modified Harris and Ewalt index

Site	N	Kappa	Std. Error	P*	Site	N	Kappa	Std. Error	P*
DV16	20	0,837	0,107	0,000	DV46	17	0,417	0,188	0,022
V16	20	0,736	0,136	0,000	V46	17	0,370	0,165	0,015
DV15	24	0,819	0,096	0,000	DV45	25	0,722	0,112	0,000
V15	24	0,443	0,136	0,003	V45	25	0,636	0,149	0,000
DV14	22	0,808	0,097	0,000	DV44	29	0,747	0,102	0,000
V14	22	0,456	0,144	0,001	V44	29	0,708	0,115	0,000
DV13	30	0,770	0,090	0,000	DV43	30	0,687	0,113	0,000
V13	30	0,619	0,133	0,000	V43	30	0,436	0,135	0,001
DV12	30	0,537	0,131	0,000	DV42	30	0,693	0,117	0,000
V12	30	0,591	0,129	0,000	V42	30	0,479	0,146	0,000
DV11	30	0,679	0,117	0,000	DV41	30	0,607	0,134	0,000
V11	30	0,595	0,132	0,000	V41	30	0,643	0,132	0,000
MV21	30	0,565	0,120	0,000	MV31	30	0,707	0,107	0,000
V21	30	0,503	0,139	0,002	V31	30	0,515	0,141	0,000
MV22	30	0,898	0,071	0,000	MV32	30	0,890	0,075	0,000
V22	30	0,932	0,067	0,000	V32	30	0,623	0,139	0,000
MV23	30	0,632	0,104	0,000	MV33	30	0,738	0,110	0,000
V23	30	0,626	0,132	0,000	V33	30	0,786	0,115	0,000
MV24	23	0,880	0,082	0,000	MV34	28	0,802	0,090	0,000
V24	23	0,611	0,133	0,000	V34	28	0,811	0,105	0,000
MV25	21	0,666	0,123	0,000	MV35	26	0,738	0,103	0,000
V25	21	0,566	0,148	0,000	V35	26	0,671	0,124	0,000
MV26	21	0,714	0,126	0,000	MV36	17	0,759	0,129	0,000
V26	21	0,849	0,101	0,000	V36	17	0,717	0,152	0,000
DO16	20	0,660	0,154	0,000	DO46	17	0,320	0,209	0,148
O16	20	0,580	0,163	0,001	O46	17	0,803	0,129	0,000
DO15	24	0,695	0,118	0,000	DO45	25	0,582	0,141	0,000
O15	24	0,641	0,145	0,000	O45	25	0,556	0,158	0,000
DO14	22	0,634	0,124	0,000	DO44	29	0,479	0,115	0,000
O14	22	0,621	0,136	0,000	O44	29	0,640	0,125	0,000
DO13	30	0,608	0,113	0,000	DO43	30	0,715	0,116	0,000
O13	30	0,601	0,117	0,000	O43	30	0,529	0,142	0,000
DO12	30	0,714	0,100	0,000	DO42	30	0,533	0,137	0,000
O12	30	0,805	0,090	0,000	O42	30	0,602	0,154	0,000
DO11	30	0,852	0,082	0,000	DO41	30	0,420	0,135	0,000
O11	30	0,670	0,113	0,000	O41	30	0,403	0,142	0,005
MO21	30	0,867	0,072	0,000	MO31	30	0,431	0,137	0,000
O21	30	0,568	0,120	0,000	O31	30	0,737	0,125	0,000
MO22	30	0,744	0,100	0,000	MO32	30	0,549	0,142	0,000
O22	30	0,474	0,133	0,000	O32	30	0,873	0,087	0,000
MO23	30	0,685	0,102	0,000	MO33	30	0,423	0,151	0,000
O23	30	0,777	0,105	0,000	O33	30	0,740	0,119	0,000
MO24	23	0,568	0,125	0,000	MO34	28	0,552	0,120	0,000
O24	23	0,619	0,136	0,000	O34	28	0,564	0,139	0,000
MO25	21	0,627	0,120	0,000	MO35	26	0,662	0,114	0,000
O25	21	0,550	0,163	0,000	O35	26	0,735	0,119	0,000
MO26	21	0,558	0,150	0,000	MO36	17	0,548	0,157	0,001
O26	21	0,650	0,156	0,000	O36	17	0,712	0,150	0,000

DV: Disto-vestibule, V: Vestibule, MV: Mesio-vestibule, DO: Disto-oral, O: Oral, MO: Mesio-oral, *Kappa test, $p < 0.05$.

Examiner-3 showed intra-examiner total kappa value of 0,684 for 2532 sites with Std. Error of 0,012 (P=0,000).

6.2.1.2. Seymour et al. index

Each gingival unit's measurement value according to Seymour et al. index (Seymour et al., 1985) was compared between the first and second time evaluations for both the vertical and horizontal components.

The intra-examiner's results of Examiner-1 using vertical component of Seymour et al. index (Seymour et al., 1985) are shown in Table 6.5.a. Examiner-1 showed intra-examiner total kappa value of 0,823 for 20 papillae with Std. Error of 0,019 (P=0,000). The intra-examiner's results of Examiner-1 using horizontal component of Seymour et al. index (Seymour et al., 1985) revealed intra-examiner total kappa value of 0,876 for 20 papillae with Std. Error of 0,017 (P=0,000) (Table 6.5.b).

The intra-examiner's results of Examiner-2 using vertical component of Seymour et al. index (Seymour et al., 1985) are listed in Table 6.6.a expressing intra-examiner total kappa value of 0,512 for 20 papillae with Std. Error of 0,027 (P=0,000). The intra-examiner's results of Examiner-2 using horizontal component of Seymour et al. index (Seymour et al., 1985) manifested intra-examiner total kappa value of 0,724 for 20 papillae with Std. Error of 0,024 (P=0,000) (Table 6.6.b).

The intra-examiner's results of Examiner-3 using vertical component of Seymour et al. index (Seymour et al., 1985) displayed intra-examiner total kappa value of 0,791 for 20 papillae with Std. Error of 0,022 (P=0,000) (Table 6.7.a). The intra-examiner's results of Examiner-3 using horizontal component of Seymour et al. index (Seymour et al., 1985) presented a total kappa value of 0,784 for 20 papillae with Std. Error of 0,023 (P value=0,000) (Table 6.7.b).

Table 6.5.a. Reliability of Examiner-1 measuring vertical component of Seymour et al. index.

Papillae	Kappa	Std. Error	P*
Maxilla			
V13-12	0,732	0,120	0,000
V12-11	0,842	0,087	0,000
V11-21	0,478	0,147	0,001
V21-22	0,839	0,090	0,000
V22-23	0,857	0,098	0,000
O13-12	0,763	0,114	0,000
O12-11	0,708	0,112	0,000
O11-21	0,810	0,095	0,000
O21-22	0,873	0,087	0,000
O22-23	0,826	0,095	0,000
Mandible			
V43-42	0,905	0,065	0,000
V42-41	0,713	0,106	0,000
V41-31	0,767	0,094	0,000
V31-32	0,798	0,092	0,000
V32-33	0,749	0,099	0,000
O43-42	0,801	0,088	0,000
O42-41	0,712	0,103	0,000
O41-31	0,887	0,076	0,000
O31-32	0,701	0,105	0,000
O32-33	0,751	0,100	0,000
Total	0,823	0,019	0,000

V: Vestibule, O: Oral, *Kappa test, $p < 0.05$.

Table 6.5.b. Reliability of Examiner-1 measuring horizontal component of Seymour et al. index.

Papillae	Kappa	Std. Error	P*
Maxilla			
V13-12	0,888	0,075	0,000
V12-11	0,894	0,072	0,000
V11-21	0,943	0,056	0,000
V21-22	0,835	0,090	0,000
V22-23	0,820	0,100	0,000
O13-12	0,846	0,084	0,000
O12-11	0,840	0,089	0,000
O11-21	0,849	0,083	0,000
O21-22	0,741	0,107	0,000
O22-23	0,946	0,053	0,000
Mandible			
V43-42	1,000	0,000	0,000
V42-41	0,873	0,084	0,000
V41-31	0,740	0,107	0,000
V31-32	0,934	0,065	0,000
V32-33	0,902	0,089	0,000
O43-42	0,751	0,112	0,000
O42-41	0,895	0,072	0,000
O41-31	0,838	0,089	0,000
O31-32	0,949	0,050	0,000
O32-33	0,767	0,109	0,000
Total	0,876	0,017	0,000

V: Vestibule, O: Oral, *Kappa test, $p < 0.05$.

Table 6.6.a. Reliability of Examiner-2 measuring vertical component of Seymour et al. index.

Papillae	Kappa	Std. Error	P*
Maxilla			
V13-12	0,468	0,124	0,000
V12-11	0,279	0,128	0,017
V11-21	0,313	0,148	0,014
V21-22	0,528	0,128	0,000
V22-23	0,482	0,121	0,000
O13-12	0,566	0,123	0,000
O12-11	0,291	0,132	0,012
O11-21	0,409	0,125	0,001
O21-22	0,438	0,125	0,000
O22-23	0,569	0,117	0,000
Mandible			
V43-42	0,537	0,140	0,000
V42-41	0,566	0,160	0,000
V41-31	0,570	0,116	0,000
V31-32	0,292	0,119	0,014
V32-33	0,837	0,085	0,000
O43-42	0,425	0,119	0,000
O42-41	0,414	0,117	0,000
O41-31	0,287	0,121	0,004
O31-32	0,349	0,127	0,001
O32-33	0,552	0,118	0,000
Total	0,512	0,027	0,000

V: Vestibule, O: Oral, *Kappa test, $p < 0.05$.

Table 6.6.b. Reliability of Examiner-2 measuring horizontal component of Seymour et al. index.

Papillae	Kappa	Std. Error	P*
Maxilla			
V13-12	0,670	0,116	0,000
V12-11	0,679	0,116	0,000
V11-21	0,453	0,111	0,000
V21-22	0,684	0,118	0,000
V22-23	0,777	0,104	0,000
O13-12	0,749	0,102	0,000
O12-11	0,646	0,113	0,000
O11-21	0,600	0,119	0,000
O21-22	0,601	0,119	0,000
O22-23	0,749	0,103	0,000
Mandible			
V43-42	0,836	0,113	0,000
V42-41	0,745	0,116	0,000
V41-31	0,737	0,106	0,000
V31-32	0,813	0,100	0,000
V32-33	0,744	0,141	0,000
O43-42	0,757	0,112	0,000
O42-41	0,783	0,099	0,000
O41-31	0,741	0,106	0,000
O31-32	0,767	0,108	0,000
O32-33	0,697	0,116	0,000
Total	0,724	0,024	0,000

V: Vestibule, O: Oral, *Kappa test, $p < 0.05$.

Table 6.7.a. Reliability of Examiner-3 measuring vertical component of Seymour et al. index.

Papillae	Kappa	Std. Error	P*
Maxilla			
V13-12	0,828	0,093	0,000
V12-11	0,795	0,092	0,000
V11-21	0,790	0,116	0,000
V21-22	0,750	0,102	0,000
V22-23	0,932	0,067	0,000
O13-12	0,943	0,056	0,000
O12-11	0,753	0,134	0,000
O11-21	0,772	0,118	0,000
O21-22	0,678	0,139	0,000
O22-23	0,846	0,106	0,000
Mandible			
V43-42	0,729	0,110	0,000
V42-41	0,653	0,109	0,000
V41-31	0,715	0,104	0,000
V31-32	0,793	0,094	0,000
V32-33	0,673	0,122	0,000
O43-42	0,867	0,091	0,000
O42-41	0,740	0,121	0,000
O41-31	0,672	0,127	0,000
O31-32	0,881	0,082	0,000
O32-33	0,637	0,130	0,000
Total	0,791	0,022	0,000

V: Vestibule, O: Oral, *Kappa test, $p < 0.05$.

Table 6.7.b. Reliability of Examiner-3 measuring horizontal component of Seymour et al. index.

Papillae	Kappa	Std. Error	P*
Maxilla			
V13-12	0,889	0,076	0,000
V12-11	0,677	0,114	0,000
V11-21	0,884	0,078	0,000
V21-22	0,774	0,102	0,000
V22-23	0,757	0,112	0,000
O13-12	0,893	0,073	0,000
O12-11	0,624	0,126	0,000
O11-21	0,747	0,101	0,000
O21-22	0,773	0,106	0,000
O22-23	0,763	0,109	0,000
Mandible			
V43-42	0,799	0,111	0,000
V42-41	0,806	0,101	0,000
V41-31	0,725	0,111	0,000
V31-32	0,765	0,108	0,000
V32-33	0,703	0,116	0,000
O43-42	0,771	0,107	0,000
O42-41	0,890	0,073	0,000
O41-31	0,770	0,108	0,000
O31-32	0,730	0,105	0,000
O32-33	0,729	0,126	0,000
Total	0,784	0,023	0,000

V: Vestibule, O: Oral, *Kappa test, $p < 0.05$.

6.2.1.3. King et al. index

Each gingival unit's measurement value according to King et al. index (King et al., 1993) was compared between the first and second time evaluations for both the vertical and horizontal components.

The intra-examiner's results of Examiner-1 using vertical component of King et al. index (King et al., 1993) showed intra-examiner total kappa value of 0,855 for 20 papillae with Std. Error of 0,018 (P=0,000) (Table 6.8.a). The intra-examiner's results of Examiner-1 using horizontal component of King et al. index (King et al., 1993) revealed total kappa value of 0,868 for 20 papillae with Std. Error of 0,018 (P=0,000) (Table 6.8.b)

The intra-examiner's results of Examiner-2 using vertical component of King et al. index (King et al., 1993) are displayed in Table 6.9.a showing intra-examiner total kappa value of 0,724 for 20 papillae with Std. Error of 0,024 (P=0,000). The intra-examiner's results of Examiner-2 using horizontal component of King et al. index (King et al., 1993) manifested total kappa value of 0,587 for 20 papillae with Std. Error of 0,026 (P=0,000) (Table 6.9.b).

The intra-examiner's results of Examiner-3 using vertical component of King et al. index (King et al., 1993) are expressed in Table 6.10.a revealing intra-examiner total kappa value of 0,653 for 20 papillae with Std. Error of 0,026 (P=0,000). The intra-examiner's results of Examiner-3 using horizontal component of King et al. index (King et al., 1993) presented intra-examiner total kappa value of 0,787 for 20 papillae with Std. Error of 0,022 (P=0,000) (Table 6.10.b).

Table 6.8.a. Reliability of Examiner-1 measuring vertical component of King et al. index.

Papillae	Kappa	Std. Error	P*
Maxilla			
V13-12	0,944	0,055	0,000
V12-11	0,784	0,100	0,000
V11-21	0,660	0,112	0,000
V21-22	0,646	0,120	0,000
V22-23	0,903	0,066	0,000
O13-12	0,839	0,087	0,000
O12-11	0,892	0,072	0,000
O11-21	0,954	0,045	0,000
O21-22	0,694	0,112	0,000
O22-23	0,908	0,063	0,000
Mandible			
V43-42	0,755	0,104	0,000
V42-41	0,812	0,097	0,000
V41-31	0,854	0,080	0,000
V31-32	0,896	0,071	0,000
V32-33	0,756	0,110	0,000
O43-42	0,895	0,072	0,000
O42-41	0,901	0,068	0,000
O41-31	1,000	0,000	0,000
O31-32	0,860	0,077	0,000
O32-33	0,855	0,080	0,000
Total	0,855	0,018	0,000

V: Vestibule, O: Oral, *Kappa test, $p < 0.05$.

Table 6.8.b. Reliability of Examiner-1 measuring horizontal component of King et al. index.

Papillae	Kappa	Std. Error	P*
Maxilla			
V13-12	0,768	0,107	0,000
V12-11	0,947	0,052	0,000
V11-21	0,943	0,056	0,000
V21-22	0,831	0,094	0,000
V22-23	0,762	0,106	0,000
O13-12	0,899	0,069	0,000
O12-11	0,894	0,072	0,000
O11-21	0,700	0,108	0,000
O21-22	0,840	0,085	0,000
O22-23	0,945	0,053	0,000
Mandible			
V43-42	1,000	0,000	0,000
V42-41	0,876	0,082	0,000
V41-31	0,791	0,100	0,000
V31-32	0,867	0,088	0,000
V32-33	0,917	0,082	0,000
O43-42	0,626	0,132	0,000
O42-41	0,895	0,072	0,000
O41-31	0,837	0,090	0,000
O31-32	0,949	0,051	0,000
O32-33	0,835	0,089	0,000
Total	0,868	0,018	0,000

V: Vestibule, O: Oral, *Kappa test, $p < 0.05$.

Table 6.9.a. Reliability of Examiner-2 measuring vertical component of King et al. index.

Papillae	Kappa	Std. Error	P*
Maxilla			
V13-12	0,726	0,111	0,000
V12-11	0,587	0,131	0,000
V11-21	0,618	0,113	0,000
V21-22	0,381	0,129	0,000
V22-23	0,545	0,112	0,000
O13-12	0,522	0,105	0,000
O12-11	0,390	0,134	0,001
O11-21	0,478	0,119	0,000
O21-22	0,354	0,138	0,002
O22-23	0,590	0,115	0,000
Mandible			
V43-42	0,697	0,113	0,000
V42-41	0,758	0,110	0,000
V41-31	0,606	0,115	0,000
V31-32	0,586	0,122	0,000
V32-33	0,250	0,143	0,101
O43-42	0,370	0,113	0,001
O42-41	0,620	0,111	0,000
O41-31	0,700	0,112	0,000
O31-32	0,574	0,113	0,000
O32-33	0,648	0,116	0,000
Total	0,724	0,024	0,000

V: Vestibule, O: Oral, *Kappa test, $p < 0.05$.

Table 6.9.b. Reliability of Examiner-2 measuring horizontal component of King et al. index.

Papillae	Kappa	Std. Error	P*
Maxilla			
V13-12	0,627	0,130	0,000
V12-11	0,840	0,087	0,000
V11-21	0,372	0,133	0,005
V21-22	0,731	0,110	0,000
V22-23	0,884	0,080	0,000
O13-12	0,746	0,105	0,000
O12-11	0,592	0,123	0,000
O11-21	0,603	0,119	0,000
O21-22	0,590	0,126	0,000
O22-23	0,604	0,116	0,000
Mandible			
V43-42	0,797	0,103	0,000
V42-41	0,727	0,115	0,000
V41-31	0,840	0,086	0,000
V31-32	0,610	0,141	0,000
V32-33	0,526	0,149	0,000
O43-42	0,670	0,120	0,000
O42-41	0,783	0,099	0,000
O41-31	0,700	0,108	0,000
O31-32	0,676	0,119	0,000
O32-33	0,465	0,145	0,000
Total	0,587	0,026	0,000

V: Vestibule, O: Oral, *Kappa test, $p < 0.05$.

Table 6.10.a. Reliability of Examiner-3 measuring vertical component of King et al. index.

Papillae	Kappa	Std. Error	P*
Maxilla			
V13-12	0,785	0,103	0,000
V12-11	0,600	0,146	0,000
V11-21	0,554	0,119	0,000
V21-22	0,708	0,124	0,000
V22-23	0,552	0,141	0,000
O13-12	0,690	0,106	0,000
O12-11	0,338	0,138	0,018
O11-21	0,615	0,118	0,000
O21-22	0,669	0,116	0,000
O22-23	0,712	0,107	0,000
Mandible			
V43-42	0,439	0,132	0,000
V42-41	0,693	0,127	0,000
V41-31	0,590	0,137	0,000
V31-32	0,534	0,133	0,000
V32-33	0,889	0,076	0,000
O43-42	0,731	0,107	0,000
O42-41	0,501	0,128	0,000
O41-31	0,618	0,128	0,000
O31-32	0,617	0,111	0,000
O32-33	0,639	0,119	0,000
Total	0,653	0,026	0,000

V: Vestibule, O: Oral, *Kappa test, $p < 0.05$.

Table 6.10.b. Reliability of Examiner-3 measuring horizontal component of King et al. index.

Papillae	Kappa	Std. Error	P*
Maxilla			
V13-12	0,889	0,076	0,000
V12-11	0,677	0,114	0,000
V11-21	0,884	0,078	0,000
V21-22	0,774	0,102	0,000
V22-23	0,757	0,112	0,000
O13-12	0,893	0,073	0,000
O12-11	0,624	0,126	0,000
O11-21	0,747	0,101	0,000
O21-22	0,773	0,106	0,000
O22-23	0,817	0,100	0,000
Mandible			
V43-42	0,799	0,111	0,000
V42-41	0,806	0,101	0,000
V41-31	0,725	0,111	0,000
V31-32	0,765	0,108	0,000
V32-33	0,703	0,116	0,000
O43-42	0,771	0,107	0,000
O42-41	0,890	0,073	0,000
O41-31	0,770	0,108	0,000
O31-32	0,730	0,105	0,000
O32-33	0,729	0,126	0,000
Total	0,787	0,022	0,000

V: Vestibule, O: Oral, *Kappa test, $p < 0.05$.

6.2.1.4. Ellis et al. index

Each gingival unit's measurement value according to Ellis et al. index (Ellis et al., 2001) was compared between the first and second time evaluations.

The intra-examiner's results of Examiner-1 using Ellis et al. index (Ellis et al., 1993) are shown in Table 6.11 expressing intra-examiner total kappa value of 0,855 for 10 papillae with Std. Error of 0,025 (P=0,000).

The intra-examiner's results of Examiner-2 using Ellis et al. index (Ellis et al., 1993) revealed intra-examiner total kappa value of 0,758 for 10 papillae with Std. Error of 0,030 (P=0,000) (Table 6.12).

The intra-examiner's results of Examiner-3 using Ellis et al. index (Ellis et al., 1993) displayed intra-examiner total kappa value of 0,830 for 10 papillae with Std. Error of 0,027 (P=0,000) as presented in Table 6.13.

Table 6.11. Reliability of Examiner-1 measuring Ellis et al. index

Papillae	Kappa	Std. Error	P*
13-12	0,843	0,085	0,000
12-11	0,717	0,101	0,000
11-21	0,813	0,089	0,000
21-22	0,904	0,066	0,000
22-23	0,812	0,087	0,000
43-42	0,848	0,080	0,000
42-41	0,930	0,066	0,000
41-31	0,736	0,101	0,000
31-32	0,887	0,075	0,000
32-33	1,000	0,000	0,000
Total	0,855	0,025	0,000

*Kappa test, $p < 0.05$.

Table 6.12. Reliability of Examiner-2 measuring Ellis et al. index

Papillae	Kappa	Std. Error	p*
13-12	0,754	0,099	0,000
12-11	0,766	0,092	0,000
11-21	0,516	0,127	0,000
21-22	0,815	0,086	0,000
22-23	0,678	0,107	0,000
43-42	0,854	0,080	0,000
42-41	0,860	0,087	0,000
41-31	0,697	0,105	0,000
31-32	0,690	0,118	0,000
32-33	0,799	0,090	0,000
Total	0,758	0,030	0,000

*Kappa test, $p < 0.05$.

Table 6.13. Reliability of Examiner-3 measuring Ellis et al. index

Papillae	Kappa	Std. Error	p*
13-12	0,746	0,103	0,000
12-11	0,816	0,085	0,000
11-21	0,862	0,075	0,000
21-22	0,805	0,090	0,000
22-23	0,909	0,062	0,000
43-42	1,000	0,000	0,000
42-41	0,811	0,103	0,000
41-31	0,803	0,088	0,000
31-32	0,660	0,126	0,000
32-33	0,747	0,100	0,000
Total	0,830	0,027	0,000

*Kappa test, $p < 0.05$.

6.2.2. Inter-examiner reliability

6.2.2.1. Modified Harris and Ewalt index

Each gingival unit's measurement value of the first time evaluations according to modified Harris and Ewalt index (Prasad et al., 1998) was compared between Examiner-1 and Examiner-2; Examiner-1 and Examiner-3; and Examiner-2 and Examiner-3. The inter-examiner's results of Examiner-1-2, Examiner-1-3, and Examiner-2-3 using modified Harris and Ewalt index are shown in Tables 6.14, 6.15, 6.16, respectively.

Table 6.14. Reliability of Examiner-1-2 measuring modified Harris and Ewalt index

Site	N	Kappa	Std. Error	p*	Site	N	Kappa	Std. Error	p*
DV16	20	0,203	0,141	0,114	DV46	17	,428	0,165	0,003
V16	20	0,474	0,140	0,000	V46	17	,295	0,170	0,028
DV15	24	0,269	0,131	0,014	DV45	25	,332	0,132	0,002
V15	24	0,305	0,117	0,003	V45	25	,117	0,118	0,268
DV14	22	0,396	0,130	0,001	DV44	29	,381	0,122	0,000
V14	22	0,414	0,132	0,000	V44	29	,205	0,146	0,094
DV13	30	0,427	0,115	0,000	DV43	30	,137	0,113	0,210
V13	30	0,167	0,099	0,080	V43	30	,188	0,121	0,097
DV12	30	0,433	0,122	0,000	DV42	30	,310	0,116	0,002
V12	30	0,043	0,120	0,675	V42	30	,289	0,099	0,001
DV11	30	0,424	0,115	0,000	DV41	30	0,437	0,118	0,000
V11	30	0,404	0,139	0,001	V41	30	0,094	0,119	0,300
MV21	30	0,083	0,091	0,379	MV31	30	0,373	0,117	0,000
V21	30	0,293	0,121	0,003	V31	30	0,303	0,117	0,001
MV22	30	0,212	0,113	0,017	MV32	30	0,271	0,109	0,002
V22	30	0,031	0,105	0,769	V32	30	0,060	0,100	0,511
MV23	30	0,177	0,087	0,052	MV33	30	0,093	0,092	0,222
V23	30	0,047	0,099	0,617	V33	30	0,208	0,111	0,049
MV24	23	0,307	0,139	0,014	MV34	28	-0,053	0,073	0,488
V24	23	0,144	0,107	0,118	V34	28	0,175	0,103	0,088
MV25	21	0,478	0,136	0,000	MV35	26	-0,081	0,082	0,395
V25	21	0,175	0,118	0,083	V35	26	-0,013	0,124	0,907
MV26	21	-0,023	0,137	0,860	MV36	17	-0,005	0,155	0,973
V26	21	0,216	0,086	0,003	V36	17	0,019	0,108	0,876
DO16	20	0,178	0,136	0,160	DO46	17	0,026	0,156	0,866
O16	20	0,015	0,145	0,923	O46	17	-0,028	0,150	0,812
DO15	24	0,276	0,144	0,026	DO45	25	0,118	0,145	0,304
O15	24	0,035	0,131	0,782	O45	25	0,175	0,160	0,148
DO14	22	0,282	0,143	0,012	DO44	29	0,306	0,105	0,001
O14	22	0,353	0,158	0,007	O44	29	0,202	0,119	0,047
DO13	30	0,304	0,108	0,001	DO43	30	0,391	0,117	0,000
O13	30	0,286	0,123	0,004	O43	30	0,274	0,122	0,009
DO12	30	0,076	0,111	0,449	DO42	30	0,432	0,117	0,000
O12	30	0,339	0,114	0,001	O42	30	0,086	0,132	0,448
DO11	30	0,188	0,114	0,083	DO41	30	0,180	0,114	0,097
O11	30	0,286	0,113	0,005	O41	30	0,089	0,121	0,433
MO21	30	0,114	0,092	0,187	MO31	30	0,273	0,122	0,008
O21	30	0,366	0,118	0,001	O31	30	0,113	0,126	0,279
MO22	30	0,290	0,111	0,004	MO32	30	0,506	0,122	0,000
O22	30	0,160	0,124	0,135	O32	30	0,125	0,115	0,243
MO23	30	0,128	0,096	0,191	MO33	30	0,323	0,123	0,004
O23	30	0,122	0,114	0,239	O33	30	0,147	0,116	0,180
MO24	23	0,161	0,133	0,100	MO34	28	0,136	0,111	0,190
O24	23	-0,005	0,135	0,964	O34	28	0,248	0,116	0,014
MO25	21	0,155	0,147	0,176	MO35	26	0,431	0,126	0,000
O25	21	0,098	0,129	0,384	O35	26	0,045	0,135	0,712
MO26	21	-0,085	0,110	0,454	MO36	17	0,364	0,141	0,006
O26	21	0,346	0,147	0,016	O36	17	0,145	0,153	0,331

DV: Disto-vestibule, V: Vestibule, MV: Mesio-vestibule, DO: Disto-oral, O: Oral, MO: Mesio-oral, *Kappa test, $p < 0.05$.

Examiner-1 and Examiner-2 showed inter-examiner total kappa value of 0,071 for 2532 sites with Std. Error of 0,012 ($P=0,000$).

Table 6.15. Reliability of Examiner-1-3 measuring modified Harris and Ewalt index

Site	N	Kappa	Std. Error	P*	Site	N	Kappa	Std. Error	P*
DV16	20	0,370	0,147	0,005	DV46	17	-0,184	0,140	0,179
V16	20	0,455	0,162	0,010	V46	17	0,150	0,153	0,318
DV15	24	0,564	0,143	0,000	DV45	25	0,320	0,139	0,007
V15	24	0,028	0,088	0,787	V45	25	0,205	0,152	0,104
DV14	22	0,366	0,137	0,004	DV44	29	0,497	0,139	0,000
V14	22	0,288	0,155	0,031	V44	29	-0,020	0,121	0,857
DV13	30	0,444	0,113	0,000	DV43	30	0,162	0,144	0,213
V13	30	0,295	0,145	0,023	V43	30	-0,014	0,123	0,901
DV12	30	0,189	0,125	0,125	DV42	30	0,268	0,119	0,014
V12	30	0,039	0,115	0,726	V42	30	-0,052	0,086	0,561
DV11	30	0,277	0,133	0,025	DV41	30	0,144	0,130	0,212
V11	30	0,195	0,154	0,099	V41	30	0,099	0,090	0,259
MV21	30	-0,054	0,108	0,626	MV31	30	0,141	0,120	0,194
V21	30	-0,018	0,114	0,872	V31	30	0,159	0,109	0,109
MV22	30	0,178	0,136	0,139	MV32	30	0,357	0,134	0,001
V22	30	-0,169	0,071	0,090	V32	30	0,000	0,091	1,000
MV23	30	0,147	0,126	0,193	MV33	30	0,250	0,123	0,035
V23	30	0,085	0,118	0,419	V33	30	0,088	0,111	0,388
MV24	23	0,169	0,135	0,182	MV34	28	0,185	0,124	0,082
V24	23	0,172	0,138	0,183	V34	28	0,038	0,126	0,727
MV25	21	0,160	0,176	0,249	MV35	26	0,121	0,125	0,241
V25	21	0,154	0,149	0,237	V35	26	-0,190	0,104	0,096
MV26	21	0,571	0,133	0,000	MV36	17	0,215	0,139	0,135
V26	21	0,027	0,158	0,857	V36	17	0,138	0,142	0,139
DO16	20	0,440	0,142	0,002	DO46	17	0,280	0,127	0,046
O16	20	0,182	0,160	0,223	O46	17	0,256	0,185	0,128
DO15	24	0,301	0,128	0,009	DO45	25	0,092	0,103	0,317
O15	24	0,267	0,131	0,027	O45	25	0,267	0,157	0,041
DO14	22	0,330	0,137	0,001	DO44	29	0,117	0,087	0,174
O14	22	0,167	0,158	0,228	O44	29	0,044	0,119	0,725
DO13	30	0,213	0,116	0,036	DO43	30	0,307	0,119	0,004
O13	30	0,226	0,125	0,035	O43	30	0,063	0,128	0,596
DO12	30	0,292	0,111	0,004	DO42	30	0,143	0,125	0,222
O12	30	0,147	0,132	0,187	O42	30	0,016	0,079	0,864
DO11	30	0,295	0,125	0,012	DO41	30	0,270	0,122	0,021
O11	30	0,384	0,117	0,000	O41	30	0,018	0,110	0,866
MO21	30	0,190	0,122	0,056	MO31	30	0,261	0,143	0,035
O21	30	0,073	0,121	0,578	O31	30	-0,061	0,101	0,516
MO22	30	0,311	0,121	0,004	MO32	30	0,023	0,131	0,832
O22	30	0,095	0,113	0,428	O32	30	0,031	0,118	0,761
MO23	30	0,286	0,110	0,006	MO33	30	0,110	0,086	0,244
O23	30	0,195	0,122	0,093	O33	30	0,121	0,137	0,327
MO24	23	0,319	0,125	0,002	MO34	28	0,221	0,113	0,036
O24	23	0,490	0,137	0,000	O34	28	0,053	0,117	0,610
MO25	21	0,133	0,136	0,244	MO35	26	0,182	0,134	0,123
O25	21	0,314	0,134	0,005	O35	26	0,264	0,139	0,047
MO26	21	0,006	0,111	0,953	MO36	17	0,167	0,117	0,192
O26	21	-0,047	0,128	0,689	O36	17	-0,074	0,089	0,479

DV: Disto-vestibule, V: Vestibule, MV: Mesio-vestibule, DO: Disto-oral, O: Oral, MO: Mesio-oral, *Kappa test, $p < 0.05$.

Examiner-1 and Examiner-3 showed inter-examiner total kappa value of 0,042 for 2532 sites with Std. Error of 0,014 ($P=0,001$).

Table 6.16. Reliability of Examiner-2-3 measuring modified Harris and Ewalt index

Site	N	Kappa	Std. Error	p*	Site	N	Kappa	Std. Error	p*
DV16	20	,623	,139	,000	DV46	17	,115	,182	,448
V16	20	,328	,147	,011	V46	17	-,052	,120	,698
DV15	24	,433	,130	,000	DV45	25	,366	,123	,000
V15	24	,259	,112	,016	V45	25	,076	,133	,532
DV14	22	,626	,127	,000	DV44	29	,482	,115	,000
V14	22	,288	,143	,014	V44	29	,224	,139	,086
DV13	30	,420	,114	,000	DV43	30	,265	,115	,020
V13	30	,160	,095	,078	V43	30	,262	,126	,015
DV12	30	,211	,115	,061	DV42	30	,148	,107	,131
V12	30	,262	,112	,009	V42	30	,043	,094	,613
DV11	30	,226	,123	,042	DV41	30	,220	,107	,017
V11	30	,114	,146	,312	V41	30	,052	,099	,541
MV21	30	,256	,122	,016	MV31	30	,010	,087	,908
V21	30	,193	,112	,082	V31	30	,092	,084	,224
MV22	30	,132	,114	,180	MV32	30	,238	,104	,004
V22	30	,147	,110	,095	V32	30	,036	,078	,653
MV23	30	,224	,119	,026	MV33	30	,172	,103	,051
V23	30	,431	,118	,000	V33	30	,034	,089	,706
MV24	23	,395	,148	,001	MV34	28	,098	,101	,263
V24	23	,251	,116	,018	V34	28	,010	,082	,911
MV25	21	,280	,154	,016	MV35	26	,222	,113	,021
V25	21	,296	,132	,010	V35	26	,135	,111	,244
MV26	21	,240	,156	,058	MV36	17	,358	,167	,008
V26	21	,227	,105	,011	V36	17	,220	,151	,079
DO16	20	-,034	,131	,771	DO46	17	-,018	,109	,870
O16	20	,336	,148	,019	O46	17	,033	,141	,798
DO15	24	,410	,146	,001	DO45	25	,076	,123	,494
O15	24	,542	,137	,000	O45	25	,136	,147	,222
DO14	22	,178	,155	,141	DO44	29	-,085	,099	,393
O14	22	,125	,163	,332	O44	29	,127	,103	,216
DO13	30	,188	,117	,050	DO43	30	-,010	,089	,906
O13	30	,104	,103	,295	O43	30	,197	,118	,077
DO12	30	,146	,130	,174	DO42	30	,024	,114	,806
O12	30	,015	,113	,880	O42	30	,005	,085	,950
DO11	30	,079	,123	,492	DO41	30	,143	,128	,176
O11	30	,413	,111	,000	O41	30	-,040	,100	,713
MO21	30	,265	,106	,005	MO31	30	,281	,107	,007
O21	30	,220	,105	,047	O31	30	,215	,132	,066
MO22	30	,007	,088	,949	MO32	30	,251	,117	,008
O22	30	,189	,124	,084	O32	30	,243	,128	,040
MO23	30	,308	,121	,003	MO33	30	,251	,109	,006
O23	30	,217	,126	,049	O33	30	,300	,127	,016
MO24	23	,130	,119	,200	MO34	28	,169	,140	,104
O24	23	,189	,122	,090	O34	28	,268	,092	,001
MO25	21	,232	,148	,051	MO35	26	,246	,131	,032
O25	21	,081	,143	,505	O35	26	,054	,113	,634
MO26	21	,133	,147	,288	MO36	17	,271	,136	,021
O26	21	,133	,135	,288	O36	17	,014	,138	,917

DV: Disto-vestibule, V: Vestibule, MV: Mesio-vestibule, DO: Disto-oral, O: Oral, MO: Mesio-oral, *Kappa test, $p < 0.05$.

Examiner-2 and Examiner-3 showed inter-examiner total kappa value of 0,070 for 2532 sites with Std. Error of 0,012 (P=0,000).

6.2.2.2. Seymour et al. index

Each gingival unit's measurement value of the first time evaluations according to Seymour et al. index (Seymour et al., 1985) was compared between Examiner-1 and Examiner-2; Examiner-1 and Examiner-3; and Examiner-2 and Examiner-3 for both the vertical and horizontal components.

The inter-examiner's results of Examiner-1 and Examiner-2 using vertical component of Seymour et al. index (Seymour et al., 1985) showed inter-examiner total kappa value of 0,248 for 20 papillae with Std. Error of 0,026 (P=0,000) (Table 6.17.a). The inter-examiner's results of Examiner-1 and Examiner-2 using horizontal component of Seymour et al. index (Seymour et al., 1985) revealed inter-examiner total kappa value of 0,255 for 20 papillae with Std. Error of 0,031 (P=0,000) (Table 6.17.b).

The inter-examiner's results of Examiner-1 and Examiner-3 using vertical component of Seymour et al. index (Seymour et al., 1985) are listed in Table 6.18.a expressing inter-examiner total kappa value of 0,235 for 20 papillae with Std. Error of 0,027 (P=0,000). The inter-examiner's results of Examiner-1 and Examiner-3 using horizontal component of Seymour et al. index (Seymour et al., 1985) are displayed in Table 6.18.b with inter-examiner total kappa value of 0,626 for 20 papillae with Std. Error of 0,027 (P=0,000).

The inter-examiner's results of Examiner-2 and Examiner-3 using vertical component of Seymour et al. index (Seymour et al., 1985) manifested inter-examiner total kappa value of 0,279 for 20 papillae with Std. Error of 0,027 (P=0,000) (Table 6.19.a), and inter-examiner's total kappa value of 0,570 for 20 papillae with Std. Error of 0,032 (P=0,000) using horizontal component of Seymour et al. index (Seymour et al., 1985) as presented in Table 6.19.b.

Table 6.17.a. Reliability of Examiner-1 and Examiner-2 measuring vertical component of Seymour et al. index.

Papillae	Kappa	Std. Error	p*
Maxilla			
V13-12	0,223	0,100	0,010
V12-11	0,077	0,098	0,424
V11-21	0,365	0,138	0,004
V21-22	0,169	0,133	0,118
V22-23	0,122	0,102	0,141
O13-12	0,205	0,129	0,072
O12-11	0,062	0,118	0,565
O11-21	0,196	0,121	0,096
O21-22	0,081	0,121	0,444
O22-23	0,269	0,113	0,006
Mandible			
V43-42	0,238	0,114	0,025
V42-41	0,191	0,085	0,052
V41-31	0,272	0,132	0,013
V31-32	0,333	0,102	0,002
V32-33	0,215	0,093	0,014
O43-42	0,204	0,101	0,035
O42-41	0,182	0,101	0,041
O41-31	0,140	0,095	0,157
O31-32	0,114	0,107	0,233
O32-33	0,189	0,118	0,055
Total	0,248	0,026	0,000

V: Vestibule, O: Oral, *Kappa test, $p < 0.05$.

Table 6.17.b. Reliability of Examiner-1 and Examiner-2 measuring horizontal component of Seymour et al. index.

Papillae	Kappa	Std. Error	p*
Maxilla			
V13-12	,545	,133	,000
V12-11	,734	,110	,000
V11-21	,600	,133	,000
V21-22	,626	,125	,000
V22-23	,474	,152	,002
O13-12	,594	,126	,000
O12-11	,492	,130	,000
O11-21	,548	,127	,000
O21-22	,399	,134	,001
O22-23	,466	,117	,000
Mandible			
V43-42	,672	,153	,000
V42-41	,805	,108	,000
V41-31	,680	,118	,000
V31-32	,414	,163	,005
V32-33	,541	,153	,000
O43-42	,514	,141	,001
O42-41	,733	,106	,000
O41-31	,681	,118	,000
O31-32	,642	,109	,000
O32-33	,141	,148	,291
Total	0,255	0,031	0,000

V: Vestibule, O: Oral, *Kappa test, $p < 0.05$.

Table 6.18.a. Reliability of Examiner-1 and Examiner-3 measuring vertical component of Seymour et al. index.

Papillae	Kappa	Std. Error	P*
Maxilla			
V13-12	0,263	0,115	0,009
V12-11	0,371	0,135	0,001
V11-21	0,149	0,118	0,131
V21-22	0,306	0,134	0,005
V22-23	0,174	0,162	0,124
O13-12	0,171	0,122	0,106
O12-11	-0,023	0,137	0,839
O11-21	0,143	0,101	0,084
O21-22	0,136	0,121	0,146
O22-23	0,325	0,144	0,003
Mandible			
V43-42	0,443	0,112	0,000
V42-41	0,134	0,103	0,170
V41-31	0,149	0,118	0,144
V31-32	0,167	0,097	0,067
V32-33	0,123	0,109	0,216
O43-42	0,328	0,107	0,001
O42-41	0,102	0,084	0,230
O41-31	0,269	0,093	0,003
O31-32	0,132	0,114	0,222
O32-33	0,397	0,132	0,000
Total	0,235	0,027	0,000

V: Vestibule, O: Oral, *Kappa test, $p < 0.05$.

Table 6.18.b. Reliability of Examiner-1 and Examiner-3 measuring horizontal component of Seymour et al. index.

Papillae	Kappa	Std. Error	P
Maxilla			
V13-12	0,719	0,115	0,000
V12-11	0,786	0,099	0,000
V11-21	0,709	0,119	0,000
V21-22	0,448	0,140	0,001
V22-23	0,526	0,151	0,001
O13-12	0,694	0,109	0,000
O12-11	0,697	0,108	0,000
O11-21	0,595	0,121	0,000
O21-22	0,439	0,133	0,000
O22-23	0,387	0,108	0,000
Mandible			
V43-42	0,635	0,147	0,000
V42-41	0,485	0,145	0,004
V41-31	0,733	0,108	0,000
V31-32	0,579	0,143	0,000
V32-33	0,489	0,140	0,000
O43-42	0,501	0,154	0,001
O42-41	0,677	0,115	0,000
O41-31	0,609	0,132	0,000
O31-32	0,798	0,092	0,000
O32-33	0,443	0,148	0,001
Total	0,626	0,027	0,000

V: Vestibule, O: Oral, *Kappa test, $p < 0.05$.

Table 6.19.a. Reliability of Examiner-2 and Examiner-3 measuring vertical component of Seymour et al. index.

Papillae	Kappa	Std. Error	P
Maxilla			
V13-12	0,144	0,127	0,225
V12-11	0,188	0,115	0,097
V11-21	0,428	0,147	0,002
V21-22	0,615	0,120	0,000
V22-23	0,429	0,115	0,000
O13-12	0,392	0,130	0,001
O12-11	0,131	0,114	0,182
O11-21	0,073	0,120	0,482
O21-22	0,225	0,110	0,015
O22-23	0,298	0,111	0,001
Mandible			
V43-42	0,218	0,124	0,027
V42-41	0,180	0,093	0,058
V41-31	0,136	0,121	0,176
V31-32	0,214	0,086	0,008
V32-33	0,143	0,117	0,172
O43-42	0,115	0,101	0,184
O42-41	-0,003	0,080	0,971
O41-31	0,305	0,127	0,006
O31-32	0,299	0,129	0,010
O32-33	0,344	0,109	0,000
Total	0,279	0,027	0,000

V: Vestibule, O: Oral, *Kappa test, $p < 0.05$.

Table 6.19.b. Reliability of Examiner-2 and Examiner-3 measuring horizontal component of Seymour et al. index.

Papillae	Kappa	Std. Error	P
Maxilla			
V13-12	0,828	0,091	0,000
V12-11	0,718	0,118	0,000
V11-21	0,651	0,129	0,000
V21-22	0,619	0,127	0,000
V22-23	0,480	0,149	0,001
O13-12	0,699	0,108	0,000
O12-11	0,497	0,129	0,000
O11-21	0,544	0,124	0,000
O21-22	0,674	0,114	0,000
O22-23	0,454	0,115	0,000
Mandible			
V43-42	0,635	0,147	0,000
V42-41	0,414	0,151	0,012
V41-31	0,726	0,112	0,000
V31-32	0,511	0,148	0,000
V32-33	0,490	0,153	0,001
O43-42	0,411	0,148	0,005
O42-41	0,776	0,105	0,000
O41-31	0,728	0,112	0,000
O31-32	0,785	0,095	0,000
O32-33	0,574	0,130	0,000
Total	0,570	0,032	0,000

V: Vestibule, O: Oral, *Kappa test, $p < 0.05$

6.2.2.3. King et al. index

Each gingival unit's measurement value of the first time evaluations according to King et al. index (King et al., 1993) was compared between Examiner-1 and Examiner-2; Examiner-1 and Examiner-3; and Examiner-2 and Examiner-3 for both the vertical and horizontal components.

The inter-examiner's results of Examiner-1 and Examiner-2 using vertical component of King et al. index (King et al., 1993) are shown in Table 6.20.a. presenting inter-examiner total kappa value of 0,635 for 20 papillae with Std. Error of 0,024 (P=0,000). The inter-examiner's results of Examiner-1 and Examiner-2 using horizontal component of King et al. index (King et al., 1993) revealed inter-examiner total kappa value of 0,595 for 20 papillae with Std. Error of 0,023 (P=0,000) (Table 6.20.b).

The inter-examiner's results of Examiner-1 and Examiner-3 using vertical component of King et al. index (King et al., 1993) are listed in Table 6.21.a. Examiner-1 and Examiner-3 displayed inter-examiner total kappa value of 0,508 for 20 papillae with Std. Error of 0,030 (P=0,000). The inter-examiner's results of Examiner-1 and Examiner-3 using horizontal component of King et al. index (King et al., 1993) expressed inter-examiner total kappa value of 0,582 for 20 papillae with Std. Error of 0,028 (P=0,000) (Table 6.21.b).

The inter-examiner's results of Examiner-2 and Examiner-3 using vertical component of King et al. index (King et al., 1993) are manifested in Table 6.22.a revealing inter-examiner total kappa value of 0,372 for 20 papillae with Std. Error of 0,026 (P=0,005), and inter-examiner's total kappa value of 0,393 for 20 papillae with Std. Error of 0,024 (P=0,000). using horizontal component of King et al. index (King et al., 1993) (Table 6.22.b).

Table 6.20.a. Reliability of Examiner-1 and Examiner-2 measuring vertical component of King et al. index.

Papillae	Kappa	Std. Error	p*
Maxilla			
V13-12	0,892	0,073	0,000
V12-11	0,835	0,088	0,000
V11-21	0,667	0,108	0,000
V21-22	0,517	0,125	0,000
V22-23	0,667	0,108	0,000
O13-12	0,673	0,110	0,000
O12-11	0,488	0,134	0,000
O11-21	0,863	0,076	0,000
O21-22	0,628	0,125	0,000
O22-23	0,587	0,114	0,000
Mandible			
V43-42	0,704	0,108	0,000
V42-41	0,812	0,097	0,000
V41-31	0,809	0,090	0,000
V31-32	0,696	0,111	0,000
V32-33	0,651	0,120	0,000
O43-42	0,571	0,122	0,000
O42-41	0,799	0,094	0,000
O41-31	0,852	0,082	0,000
O31-32	0,907	0,064	0,000
O32-33	0,609	0,120	0,000
Total	0,635	0,024	0,000

V: Vestibule, O: Oral, *Kappa test, $p < 0.05$.

Table 6.20.b. Reliability of Examiner-1 and Examiner-2 measuring horizontal component of King et al. index

Papillae	Kappa	Std. Error	p*
Maxilla			
V13-12	0,379	0,132	0,009
V12-11	0,681	0,115	0,000
V11-21	0,609	0,127	0,000
V21-22	0,626	0,117	0,000
V22-23	0,489	0,128	0,001
O13-12	0,595	0,126	0,000
O12-11	0,436	0,136	0,001
O11-21	0,703	0,106	0,000
O21-22	0,511	0,117	0,000
O22-23	0,649	0,111	0,000
Mandible			
V43-42	0,568	0,149	0,000
V42-41	0,623	0,132	0,000
V41-31	0,733	0,108	0,000
V31-32	0,451	0,161	0,004
V32-33	0,681	0,150	0,000
O43-42	0,429	0,136	0,002
O42-41	0,565	0,131	0,000
O41-31	0,791	0,096	0,000
O31-32	0,586	0,120	0,000
O32-33	0,296	0,143	0,022
Total	0,595	0,023	0,000

V: Vestibule, O: Oral, *Kappa test, $p < 0.05$.

Table 6.21.a. Reliability of Examiner-1 and Examiner-3 measuring vertical component of King et al. index.

Papillae	Kappa	Std. Error	p*
Maxilla			
V13-12	0,783	0,102	0,000
V12-11	0,662	0,118	0,000
V11-21	0,443	0,137	0,000
V21-22	0,402	0,140	0,001
V22-23	0,098	0,136	0,360
O13-12	0,490	0,131	0,000
O12-11	0,398	0,138	0,004
O11-21	0,494	0,124	0,000
O21-22	0,624	0,123	0,000
O22-23	0,531	0,121	0,000
Mandible			
V43-42	0,202	0,127	0,111
V42-41	0,570	0,130	0,000
V41-31	0,501	0,130	0,000
V31-32	0,425	0,114	0,000
V32-33	0,434	0,147	0,002
O43-42	0,416	0,135	0,001
O42-41	0,648	0,121	0,000
O41-31	0,287	0,139	0,012
O31-32	0,577	0,120	0,000
O32-33	0,554	0,125	0,000
Total	0,508	0,030	0,000

V: Vestibule, O: Oral, *Kappa test, $p < 0.05$.

Table 6.21.b. Reliability of Examiner-1 and Examiner-3 measuring horizontal component of King et al. index.

Papillae	Kappa	Std. Error	p*
Maxilla			
V13-12	0,598	0,131	0,000
V12-11	0,674	0,117	0,000
V11-21	0,651	0,129	0,000
V21-22	0,431	0,143	0,002
V22-23	0,473	0,138	0,001
O13-12	0,640	0,118	0,000
O12-11	0,697	0,108	0,000
O11-21	0,541	0,128	0,000
O21-22	0,265	0,128	0,017
O22-23	0,356	0,102	0,000
Mandible			
V43-42	0,635	0,147	0,000
V42-41	0,427	0,150	0,010
V41-31	0,733	0,108	0,000
V31-32	0,511	0,148	0,000
V32-33	0,579	0,147	0,000
O43-42	0,439	0,150	0,003
O42-41	0,676	0,114	0,000
O41-31	0,620	0,123	0,000
O31-32	0,745	0,102	0,000
O32-33	0,427	0,135	0,001
Total	0,582	0,028	0,000

V: Vestibule, O: Oral, *Kappa test, $p < 0.05$.

Table 6.22.a. Reliability of Examiner-2 and Examiner-3 measuring vertical component of King et al. index.

Papillae	Kappa	Std. Error	p*
Maxilla			
V13-12	0,787	0,101	0,000
V12-11	0,813	0,102	0,000
V11-21	0,427	0,125	0,000
V21-22	0,246	0,132	0,035
V22-23	0,330	0,119	0,001
O13-12	0,576	0,116	0,000
O12-11	0,581	0,137	0,000
O11-21	0,536	0,123	0,000
O21-22	0,442	0,144	0,001
O22-23	0,766	0,097	0,000
Mandible			
V43-42	0,381	0,130	0,002
V42-41	0,646	0,123	0,000
V41-31	0,517	0,122	0,000
V31-32	0,429	0,113	0,000
V32-33	0,508	0,124	0,000
O43-42	0,645	0,131	0,000
O42-41	0,594	0,127	0,000
O41-31	0,339	0,130	0,002
O31-32	0,671	0,109	0,000
O32-33	0,752	0,101	0,000
Total	0,372	0,026	0,005

V: Vestibule, O: Oral, *Kappa test, $p < 0.05$.

Table 6.22.b. Reliability of Examiner-2 and Examiner-3 measuring horizontal component of King et al. index.

Papillae	Kappa	Std. Error	p*
Maxilla			
V13-12	0,451	0,127	0,002
V12-11	0,727	0,113	0,000
V11-21	0,602	0,131	0,000
V21-22	0,513	0,133	0,000
V22-23	0,532	0,146	0,000
O13-12	0,597	0,120	0,000
O12-11	0,453	0,130	0,000
O11-21	0,553	0,118	0,000
O21-22	0,427	0,132	0,001
O22-23	0,416	0,113	0,000
Mandible			
V43-42	0,530	0,152	0,001
V42-41	0,422	0,158	0,007
V41-31	0,890	0,076	0,000
V31-32	0,247	0,158	0,098
V32-33	0,299	0,171	0,037
O43-42	0,497	0,144	0,000
O42-41	0,607	0,128	0,000
O41-31	0,622	0,125	0,000
O31-32	0,526	0,130	0,000
O32-33	0,209	0,156	0,116
Total	0,393	0,024	0,000

V: Vestibule, O: Oral, *Kappa test, $p < 0.05$.

6.2.2.4. Ellis et al. index

Each gingival unit's measurement value of the first time evaluations according to Ellis et al. index (Ellis et al., 2001) was compared between of Examiner-1 and Examiner-2; Examiner-1 and Examiner-3; and Examiner-2 and Examiner-3.

The inter-examiner's results of Examiner-1 and Examiner-2 using Ellis et al. index (Ellis et al., 1993) are shown in Table 6.23 presenting inter-examiner total kappa value of 0,804 for 10 papillae with Std. Error of 0,028 (P=0,000).

The inter-examiner's results of Examiner-1 and Examiner-3 using Ellis et al. index (Ellis et al., 1993) are listed in Table 6.24. Examiner-1 and Examiner-3 expressed inter-examiner total kappa value of 0,717 for 10 papillae with Std. Error of 0,032 (P=0,000).

The inter-examiner's results of Examiner-2 and Examiner-3 using Ellis et al. index (Ellis et al., 1993) revealed inter-examiner total kappa value of 0,716 for 10 papillae with Std. Error of 0,032 (P=0,000) (Table 6.25).

Table 6.23. Reliability of Examiner-1 and Examiner-2 measuring Ellis et al. index

Papillae	Kappa	Std. Error	p*
13-12	0,698	0,107	0,000
12-11	0,584	0,114	0,000
11-21	0,716	0,104	0,000
21-22	0,860	0,076	0,000
22-23	0,624	0,114	0,000
43-42	1,000	0,000	0,000
42-41	1,000	0,000	0,000
41-31	0,946	0,053	0,000
31-32	0,765	0,106	0,000
32-33	0,803	0,088	0,000
Total	0,804	0,028	0,000

*Kappa test, $p < 0.05$.

Table 6.24. Reliability of Examiner-1 and Examiner-3 measuring Ellis et al. index

Papillae	Kappa	Std. Error	p*
13-12	,690	,113	,000
12-11	,635	,108	,000
11-21	,724	,101	,000
21-22	,579	,115	,000
22-23	,730	,098	,000
43-42	,950	,048	,000
42-41	,689	,116	,000
41-31	,653	,110	,000
31-32	,617	,121	,000
32-33	,756	,095	,000
Total	0,717	0,032	0,000

*Kappa test, $p < 0.05$.

Table 6.25. Reliability of Examiner-2 and Examiner-3 measuring Ellis et al. index

Papillae	Kappa	Std. Error	p*
13-12	,698	,109	,000
12-11	,814	,087	,000
11-21	,489	,123	,000
21-22	,534	,121	,000
22-23	,726	,098	,000
43-42	,950	,048	,000
42-41	,689	,116	,000
41-31	,657	,109	,000
31-32	,710	,110	,000
32-33	,752	,099	,000
Total	0,716	0,032	0,000

*Kappa test, $p < 0.05$.

7. DISCUSSION

The term G.O. is used to express the gingival dimorphism associated with multiple factors (Miranda et al., 2012). The incidence of G.O. has been accompanied with inflammatory, drug-induced and neoplastic factors (Miranda et al., 2012). Inflammatory G.O. due to plaque accumulation is the most joint reason for G.O.'s occurrence (Carranza et al., 2015). Drug-induced G.O. is a side effect related to the usage of phenytoin, CsA and C.C.B.s (Claffey, 2003; Brunet et al., 1996). Throughout the research in the field of G.O., a high number of clinical studies and case reports have been published. The subject of drug-induced G.O., specifically when it is related to phenytoin or CsA, has been extensively researched (Ellis et al., 2001). In each study concerning G.O., a G.O. index was used to report the degree of enlargement. Obstacles in the interpretation of these studies are mostly due to the variations in the criteria used for assessing the grade of the G.O. lesion (Thomason et al., 1992).

Since a large number of studies had focused on defining the influencing dosages of drugs that cause G.O. using different G.O. indices, which rely on different means of examination and criteria, a wide range of concordance occurred between the studies. Therefore, it must be obligatory for each study to use the perfect method of assessing G.O. that suits the amount of mass population, the ease of the procedure, and the financial expenses (Ellis et al., 2001). For instance, Hassell et al. (Hassell et al., 1984) presented in his literature which reviews the oral manifestations in epileptic patients under phenytoin therapy, the wide variation in the incidence of G.O. that ranges from 0% to 100% (Blair, 1939; Grob and Herold, 1972).

Previous studies reported the prevalence of drug-induced G.O. using the modified Harris and Ewalt index (Prasad et al., 1998) and Seymour et al. index (Seymour et al., 2001). While Seymour et al. index (Seymour et al., 2001) was able to detect initial G.O., modified Harris and Ewalt index (Prasad et al., 1998) lacked this ability.

Back through literature concerning the topic of G.O., a high number of indices have been utilized to detect the extent and severity of G.O. which consequently has

produced suspicion and uncertainty with regard to this clinical observation (Miranda-Ruis et al., 2012). The broad differences in results noticed between studies which used different G.O. indices might be the outcome of using non credible indices (Miranda-Ruis J et al., 2012).

The methodology to assess clinically G.O. is not universally defined. Therefore, it may be unsuitable to compare the results of G.O.'s incidence reported in different studies (King et al., 1993). Therefore, difficulties in the interpretation of these reports are in large part due to the differences in the criteria used to assess the lesion (Barclay et al., 1992).

Through research backwards in literatures, we were able to detect 24 G.O. indices. These G.O. indices depend on different means of assessment such as intra-oral readings, with the help of plaster models or photographs, or even using microscopes. A lot of these G.O. indices were consisted of modifications of previous indices described by others. The modifications could involve the grading system of the index, or even the criteria of the G.O. index itself.

In order to choose the G.O. indices to be evaluated in our study, a comprehensive observation have been employed regarding the most commonly used indices through the history of this clinical aspect. Picking out G.O. indices which depend on different materials was a significant priority of our study too where Seymour et al. index (Seymour et al., 1985) and King et al. index (King et al., 1993) depend on plaster models, and Ellis et al. index (Ellis et al., 2001) counts on intra-oral photographs. Thirdly, modified Harris and Ewalt index (Prasad et al., 1998) which covers the whole mouth aspect, not only the anterior region was included, to check how complexity of a G.O. index would interfere with the accuracy and clarity of exposing and revealing G.O.

As tools of measurement, our study used the plaster models as means to assess G.O. in modified Harris and Ewalt index (Prasad et al., 1998). Nevertheless, in the original article (Prasad et al., 1998) describing modified Harris and Ewalt index, the measurements were done intra-orally. In contrast, the only study comparing

statistically the concordance between different G.O. indices used G.O. index to measure G.O. through plaster models while it was originally described by Miller and Damm (Miller and Damm,1992) as a modification of the index described by Angelopoulos and Goaz (Angelopoulos and Goaz, 1972) to be used though intra-oral evaluation. Therefore, it is not compulsory to use these previously two mentioned indices intra-orally, especially that a second time measurement is taking place and no alterations in the gingival tissues must occur between the two trials.

The only study researching the concordance between G.O. indices by Miranda et al. (Miranda et al., 2012) used two indices depending on plaster models as the only mean of assessment. In contrast our study used four different methods to assess G.O. where three of them depend on plaster models and the fourth one uses intra-oral photographs.

The study of Miranda et al. (Miranda et al., 2012) included 12 plaster models (maxillary / mandibular) from subjects who had been under orthodontic treatment and had worn orthodontic brackets. Consequently, these patients were diagnosed with inflammatory G.O. due to the accumulation of bacterial dental plaque. On the other hand, our study consisted of 30 subjects who had 4 different types of G.O. where 18 patients had drug-induced G.O.; 9 patients with inflammatory G.O., 2 patients with pubertal G.O., and 1 patient with hereditary G.O.

Since the orthodontic brackets have been applied buccally in the study by Miranda et al. (Miranda et al., 2012), the triggered inflammatory G.O. was localized only in the buccal side, whereas G.O. in our study was generalized spontaneously throughout the whole mouth aspects.

In a study by Miranda et al. (Miranda et al., 2012), the subjects involved had finished their orthodontic treatment. Consequently, the teeth alignment had no complications such as crowdings or over proclination of anterior teeth, which the clinician might face in his daily practice. In our study, a part of included individuals

had kind of these problems which affected the clarity of readings, but rather created a more realistic step.

One G.O. index was shared between our study and Miranda et al. (Miranda et al., 2012) study, which is the horizontal component of Seymour et al. index (Seymour et al., 1985) and King et al. index (King et al., 1993).

In our study, modified Harris and Ewalt index (prasad et al., 1998) revealed an intra-examiner kappa value of 0,783 and 0,684 for Examiner-1 and Examiner-3, respectively, which presents a good degree of agreement between the 1st and 2nd measurements. On the other hand, Examiner-2 showed an intra-examiner kappa value of 0,428 which is described as a moderate degree of agreement.

Based on the vertical component of Seymour et al. index (Seymour et al., 1985), Examiner-1 had achieved a very good degree of agreement by an intra-examiner total kappa score of 0,823. Examiner-3 had scored a less degree of agreement than Examiner-1 by displaying a total kappa value of 0,791 which is considered as a good agreement. Examiner-2 revealed a total kappa value of 0,512 which is counted less than Examiner-1 and Examiner-2 and depicted as moderate.

The horizontal component of Seymour et al. index (Seymour et al., 1985) had better degrees of agreement than the vertical component suggesting a total kappa value of 0,724 and 0,784 for Examiner-2 and Examiner-3, respectively, basing a good degree of agreement. Furthermore, Examiner-1 had a very good degree of intra-examiner agreement with a total kappa value of 0,876.

The vertical component of King et al. index (King et al., 1993) showed a good degree of agreement for both Examiner-2 and Examiner-3 with total kappa values of 0,724 and 0,653, respectively. Examiner-1 had a very good agreement with 0,855 total kappa value.

According to the horizontal component of King et al. index (King et al., 1993), Examiner-1 had an intra-examiner total kappa value of 0,868 revealing a very good

agreement. Examiner-2 scored a total kappa value of 0,587 which is considered as moderate. Examiner-3 had a good degree of agreement with a total kappa value of 0,787.

Ellis et al. index (Ellis et al., 2001) showed a very good intra-examiner agreement for both Examiner-1 and Examiner-3 with a total kappa value of 0,855 and 0,830, respectively. Examiner-2 had a good agreement with a kappa value of 0,758.

In terms of inter-examiner reliability, modified Harris and Ewalt index (Prasad et al., 1998) presented poor degree of agreement between the three examiners. Inter-examiner total kappa value showed results of 0,071, 0,042, 0,070 for Examiner-1 and Examiner-2, Examiner-1 and Examiner-3, and Examiner-2 and Examiner-3, respectively.

The three examiners had also shown a fair degree of agreement in terms of inter-examiner reliability for the vertical component of Seymour et al. index (Seymour et al., 1985) with total kappa values range between 0,235-0,279.

Inter-examiner reliability for the horizontal component of Seymour et al. index (Seymour et al., 1985) ranged from fair to good degree of agreement. Inter-examiner total kappa value for Examiner-1 and Examiner-2 , Examiner-1 and Examiner-3, Examiner-2 and Examiner-3 were 0,255, 0,626, and 0,570, respectively.

The vertical component of King et al. index (King et al., 1993) expressed 3 levels of agreement as the following: Examiner-1 and Examiner-2 presented a good degree ($K=0,635$); Examiner-1 and Examiner-3 reached a moderate level of agreement ($K=0,508$); Examiner-2 and Examiner-3 had scored a fair level of agreement ($K=0,372$).

Inter-examiner total kappa values for the horizontal component of King et al. index (King et al., 1993) revealed a moderate degree of agreement for Examiner-1 and Examiner-2, Examiner-1- and Examiner-3 with total kappa values of 0,595, 0,582,

respectively. Examiner-2 and Examiner-3 inter-examiner reliability manifested a fair level of agreement with a K value of 0,393.

In term of Ellis et al. index (Ellis et al., 2001), Examiner-1 and Examiner-3, Examiner-2 and Examiner-3 displayed a good level of agreement with K values of 0,717 and 0,716, respectively. Examiner-1 and Examiner-2 expressed a very good degree of agreement with a K value of 0,804.

In the horizontal component of Seymour et al. index (Seymour et al., 1985), Miranda et al. (Miranda et al., 2012) revealed a very good degree of agreement with intra-examiner total kappa value of 0,830. In accordance, our study described a very good agreement for Examiner-1, and good agreement for Examiner-2, and Examiner-3 when this G.O. index was used. On the other hand, the horizontal component of King et al. index (King et al., 1993) in our study scored a very good level of agreement for Examiner-1 which agrees with the intra-examiner reliability achieved in the the study by Miranda et al. (Miranda et al., 2012). Examiner-2 and Examiner-3 in our study showed fair and good degree of agreement, respectively.

In the horizontal component of King et al. index (King et al., 1993), Miranda et al. (Miranda et al., 2012) presented a good agreement among examiners with a total kappa value of 0,770. In contrast, our study reached a moderate agreement between Examiner-1 and Examiner-2, Examiner-1 and Examiner-3 with kappa values of 0,595 and 0,582, respectively. Examiner-2 and Examiner-3 manifested less agreement ($K=0,393$) when the horizontal component of King et al. index (King et al., 1993) was used, considering it as fair agreement. Horizontally, Seymour et al. index (Seymour et al., 1985) expressed a very good agreement among Examiners 1-3 ($K=0,626$), good agreement among Examiners 2-3 ($K=0,570$), and fair agreement among examiners 1-2 ($K=0,255$).

While every G.O. index has its own advantages and disadvantages, the followings were noticed during our research:

- In the vertical component of Seymour et al. index (Seymour et al., 1985), there is no specific definition of the amount of encroachment of the interdental papillae for each grade, rather a figure showing the division of the half of clinical crown into three thirds. This way of classification lacks specificity and clarity.
- Although the horizontal part of both Seymour et al. (Seymour et al., 1985) and King et al. (King et al., 1992) indices, which share an identical criteria for assessing the horizontal component of G.O., have been used in a lot of studies by different authors (Miranda et al., 2001; Miranda et al., 2005), but they still do not take into consideration cases where various degrees of proclination in the anterior teeth (buccally or palatally/lingually) might occur and eventually distort the clinician from making an accurate measurement of how much extent the gingival tissues are enlarged in a labio-lingual direction.
- In various indices which depend on the gingival tissues' vertical encroachment on the clinical crown such as Aas (Aas, 19630, Angelopoulos and Goaz (Angelopoulos and Goaz, 1972), Seymour et al. (Seymour et al., 1985), Daley et al. (Daley et al., 1986), McGaw et al. (McGawet al., 1987), Pernu et al. (Pernu et al., 1992), Miller and Damm (Miller and Damm, 1992), King et al. (King et al., 1993), Somacarrera et al. (Somacarrera et al., 1994), Nery et al. (Nery et al., 1995), modified Harris and Ewalt (Prasad et al., 1998), Inglés et al. (Inglés et al., 1999), and Ellis et al. (Ellis et al., 2001), there is a lack of credibility to expect the exact degree of encroachment since the location of cemento-enamel junction is hard to define. Therefore, with this insufficient clarity it is hard for the examiner to decide how much is the percentage and degree of the coverage.
- In cases where it is not clear of how much the clinical crowns are covered due to the haziness caused by the enlarged gingival tissues, we might evaluate the opposite side to check the actual clinical crown and decide accordingly the G.O.'s grade.
- When the anterior teeth are crowded in the upper or lower jaw, the accurate reading of how much the clinical crowns are covered, or even detecting the

extent of the interdental papillae in a bucco-lingual direction is not a simple nor a straightforward procedure, but rather have a lot of complications.

- In Seymour et al. index and King et al. index, the shared horizontal component which examines the thickening of the gingival tissues in a bucco-lingual direction is much more reliable than the vertical component since it crosses all the obstacles that are due to the disappearance of the cemento-enamel junction and the crowdings in the anterior aspect.
- In cases where the patient is suffering from bruxism, and there is decreasing in the clinical crown's length, some G.O. indices', such as the vertical component of King et al. index (King et al., 1993), stay unable to accurately interact with them.

8. CONCLUSION

In general, intra-examiner total kappa values presented better results than inter-examiner findings in the 4 indices. However, intra-examiner and inter-examiner total kappa values of Ellis et al. index (Ellis et al., 2001) revealed the highest kappa values which indicates it as the most reliable method of measurement among the 4 indices.

Since Ellis et al. index (Ellis et al., 2001) does not cover the labio-lingual direction of G.O., the clinician needs a method to examine this aspect in order to create a three-dimensional G.O. measuring criteria along with the vertical (apico-incisal) aspect. Therefore, both the horizontal components of Seymour et al. index (Seymour et al., 1985), and King et al. index (King et al., 1993), which share the same grading system, could be applicable to measure the G.O. in a labio-lingual direction with total kappa values ranging between good and moderate.

9. REFERENCES

- Aas E. Hyperplasia Gingivae Diphenylhydantoinea. A Clinical, Histological, and Biochemical Study. *Acta Odontol Scand.* 1963;21:SUPPL34:31-142.
- Addy V, McElnay JC, Eyre DG, Campbell N, D'Arcy PF. Risk factors in phenytoin-induced gingival hyperplasia. *J Periodontol.* 1983;54(6):373-377.
- Amar S, Chung KM. Influence of hormonal variation on the periodontium in women. *Periodontol 2000.* 1994;6:79-87.
- Angelopoulos AP. Diphenylhydantoin gingival hyperplasia. A clinicopathological review. 1. Incidence, clinical features and histopathology. *Dent J.* 1975;41(2):103-106.
- Angelopoulos AP, Goaz PW. Incidence of diphenylhydantoin gingival hyperplasia. *Oral Surg Oral Med Oral Pathol.* 1972;34(6):898-906.
- Ayanoglou CM, Lesty C. New cementum formation induced by cyclosporin A: a histological, ultrastructural and histomorphometric study in the rat. *J Periodontal Res.* 1997;32(6):543-556.
- Babcock JR. Incidence of gingival hyperplasia associated with Dilantin therapy in a hospital population. *J Am Dent Assoc.* 1965;71(6):1447-1450.
- Bader G, Lejeune S, Messner M. Reduction of cyclosporine-induced gingival overgrowth following a change to tacrolimus. A case history involving a liver transplant patient. *J Periodontol.* 1998;69(6):729-732.
- Bader JD, Rozier RG, McFall WT, Ramsey DL. Periodontal status and treatment needs among regular dental patients. *Int Dent J.* 1988;38(4):255-260.
- Ballard JB, Butler WT. Proteins of the periodontium. Biochemical studies on the collagen and noncollagenous proteins of human gingivae. *J Oral Pathol.* 1974;3(4):176-184.
- Barak S, Engelberg IS, Hiss J. Gingival hyperplasia caused by nifedipine. Histopathologic findings. *J Periodontol.* 1987;58(9):639-642.

Barclay S, Thomason JM, Idle JR, Seymour RA. The incidence and severity of nifedipine-induced gingival overgrowth. *J Clin Periodontol*. 1992;19(5):311-314.

Bennett JA, Christian JM. Cyclosporine-induced gingival hyperplasia: case report and literature review. *J Am Dent Assoc*. 1985;111(2):272-273.

Bhaskar SN, Jacoway JR. Pyogenic granuloma--clinical features, incidence, histology, and result of treatment: report of 242 cases. *J Oral Surg*. 1966;24(5):391-398.

Blair D. The Treatment of Epilepsy by Sodium-Di-Phenyl Hydantionate (Epanutin). *Postgrad Med J*. 1939;15(167):344-350.

Bokenkamp A, Bohnhorst B, Beier C, Albers N, Offner G, Brodehl J. Nifedipine aggravates cyclosporine A-induced gingival hyperplasia. *Pediatr Nephrol*. 1994;8(2):181-185.

Borel JF, Feurer C, Magnée C, Stähelin H. Effects of the new anti-lymphocytic peptide cyclosporin A in animals. *Immunology*. 1977;32(6):1017-1025.

Brown RS, Beaver WT, Bottomley WK. On the mechanism of drug-induced gingival hyperplasia. *J Oral Pathol Med*. 1991;20(5):201-209.

Brown RS, Sein P, Corio R, Bottomley WK. Nitrendipine-induced gingival hyperplasia. First case report. *Oral Surg Oral Med Oral Pathol*. 1990;70(5):593-596.

Buckley D, Barrett A, Bilous A, Dcspas P. Wegeners granulomatosis: Are gingival lesions pathognomonic? *J Oral Med*. 1987;42:169.

Bullon P, Machuca G, Martinez-Sahuquillo A, Rios JV, Rojas J, Lacalle JR. Clinical assessment of gingival hyperplasia in patients treated with nifedipine. *J Clin Periodontol*. 1994;21(4):256-259.

Burket LW. Oral diseases in children. *J N J State Dent Soc*. 1946;17(2):18-20.

Butler RT, Kalkwarf KL, Kaldahl WB. Drug-induced gingival hyperplasia: phenytoin, cyclosporine, and nifedipine. *J Am Dent Assoc*. 1987;114(1):56-60.

Calne RY, Rolles K, White DJ, Thiru S, Evans DB, McMaster P, Dunn DC, Craddock GN, Henderson RG, Aziz S, Lewis P. Cyclosporin A initially as the only

immunosuppressant in 34 recipients of cadaveric organs: 32 kidneys, 2 pancreases, and 2 livers. *Lancet*. 1979;2(8151):1033-1036.

Calne RY, White DJ, Thiru S, Evans DB, McMaster P, Dunn DC, Craddock GN, Pentlow BD, Rolles K. Cyclosporin A in patients receiving renal allografts from cadaver donors. *Lancet*. 1978;2(8104-5):1323-1327.

Carranza F. A. HEL. Gingival Enlargement. In: A. CF, editor. *Carranza's Clinical Periodontology*. 12 ed: Elsevier; 2015.

Church LF, Jr., Brandt SK. Phenytoin-induced gingival overgrowth resulting in delayed eruption of the primary dentition. A case report. *J Periodontol*. 1984;55(1):19-21.

Ciancio SG, Yaffe SJ, Catz CC. Gingival hyperplasia and diphenylhydantoin. *J Periodontol*. 1972;43(7):411-414.

Coley C JK, Hassell T. Effect of cyclosporine A on human gingival fibroblasts *in vitro*. *J Dent Res*. 1986;65:353.

Conard GJ, Jeffay H, Boshes L, Steinberg AD. Levels of 5,5-diphenylhydantoin and its major metabolite in human serum, saliva, and hyperplastic gingiva. *J Dent Res*. 1974;53(6):1323-1329.

Dahllof G, Axio E, Modeer T. Regression of phenytoin-induced gingival overgrowth after withdrawal of medication. *Swed Dent J*. 1991;15(3):139-143.

Dahllof G, Reinholt FP, Hjerpe A, Modeer T. A quantitative analysis of connective tissue components in phenytoin-induced gingival overgrowth in children. A stereological study. *J Periodontal Res*. 1984;19(4):401-407.

Dahllof G, Modeer T. The effect of a plaque control program on the development of phenytoin-induced gingival overgrowth. A 2-year longitudinal study. *J Clin Periodontol*. 1986;13(9):845-849.

Daley TD, Wysocki GP, Day C. Clinical and pharmacologic correlations in cyclosporine-induced gingival hyperplasia. *Oral Surg Oral Med Oral Pathol*. 1986;62(4):417-421.

- Dallas B. Hyperplasia of the oral mucosa in an edentulous epileptic. *N Z Dent J.* 1963;59:54-55.
- de Oliveira Costa F, Diniz Ferreira S, de Miranda Cota LO, da Costa JE, Aguiar MA. Prevalence, severity, and risk variables associated with gingival overgrowth in renal transplant subjects treated under tacrolimus or cyclosporin regimens. *J Periodontol.* 2006;77(6):969-975.
- Dhadse PV, Yeltiwar RK, Pandilwar PK, Gosavi SR. Hereditary gingival fibromatosis. *J Indian Soc Periodontol.* 2012;16(4):606-609.
- Dreyer WP, Thomas CJ. Diphenylhydantoinate-induced hyperplasia of the masticatory mucosa in an edentulous epileptic patient. *Oral Surg Oral Med Oral Pathol.* 1978;45(5):701-706.
- Ellis JS, Seymour RA, Monkman S, Idle JR. Disposition of nifedipine in plasma and gingival crevicular fluid in relation to drug-induced gingival overgrowth. *J Periodontal Res.* 1993;28(5):373-378.
- Ellis JS, Seymour RA, Monkman SC, Idle JR. Gingival sequestration of nifedipine in nifedipine-induced gingival overgrowth. *Lancet.* 1992;339(8806):1382-1383.
- Ellis JS, Seymour RA, Robertson P, Butler TJ, Thomason JM. Photographic scoring of gingival overgrowth. *J Clin Periodontol.* 2001;28(1):81-85.
- Emerson TG. Hereditary Gingival Hyperplasia. A Family Pedigree of Four Generations. *Oral Surg Oral Med Oral Pathol.* 1965;19:1-9.
- Fattore L, Stablein M, Bredfeldt G, Semla T, Moran M, Doherty-Greenberg JM. Gingival hyperplasia: a side effect of nifedipine and diltiazem. *Spec Care Dentist.* 1991;11(3):107-109.
- Frankel SI. Dilantin sodium in the treatment of epilepsy. *Journal of the American Medical Association.* 1940;114(14):1320-1321.
- Friskopp J, Klintmalm G. Gingival enlargement. A comparison between cyclosporine and azathioprine treated renal allograft recipients. *Swed Dent J.* 1986;10(3):85-92.

- Fu E, Nieh S, Chang HL, Wang SL. Dose-dependent gingival overgrowth induced by cyclosporin in rats. *J Periodontol.* 1995;66(7):594-598.
- Fu E, Nieh S, Hsiao CT, Hsieh YD, Wikesjo UM, Shen EC. Nifedipine-induced gingival overgrowth in rats: brief review and experimental study. *J Periodontol.* 1998;69(7):765-771.
- Fuiano G, Pacchiano G, Lotito MA, Vaia E, Matarasso S, Andreucci VE. [Relations of gingival hypertrophy and blood levels of cyclosporin A in patients with renal transplants]. *Ann Ital Med Int.* 1989;4(3):161-166.
- Glickman I. Acute vitamin C deficiency and periodontal disease; the periodontal tissues of the guinea pig in acute vitamin C deficiency. *J Dent Res.* 1948;27(1):9-23.
- Glickman I. Acute vitamin C deficiency and the periodontal tissues; the effect of acute vitamin C deficiency upon the response of the periodontal tissues of the guinea pig to artificially induced inflammation. *J Dent Res.* 1948;27(2):201-210.
- Glickman I, Lewitus MP. Hyperplasia of the Gingivae Associated with Dilantin (Sodium Diphenyl Hydantoinate) Therapy. *The Journal of the American Dental Association.* 1941;28(2):199-207.
- Greenberg KV, Armitage GC, Shiboski CH. Gingival enlargement among renal transplant recipients in the era of new-generation immunosuppressants. *J Periodontol.* 2008;79(3):453-460.
- Grob PJ, Herold GE. Immunological abnormalities and hydantoins. *Br Med J.* 1972;2(5813):561-563.
- Hall WB. Dilantin hyperplasia: a preventable lesion. *J Periodontal Res Suppl.* 1969(4):36-37.
- Hallmon WW, Rossmann JA. The role of drugs in the pathogenesis of gingival overgrowth. A collective review of current concepts. *Periodontol 2000.* 1999;21:176-196.

- Hamilton DV, Carmichael DJ, Evans DB, Calne RY. Hypertension in renal transplant recipients on cyclosporin A and corticosteroids and azathioprine. *Transplant Proc.* 1982;14(3):597-600.
- Hancock RH, Swan RH. Nifedipine-induced gingival overgrowth. Report of a case treated by controlling plaque. *J Clin Periodontol.* 1992;19(1):12-14.
- Harris TH EJ. Complications following use of sodium diphenyl-hydantoinate (Dilantin) therapy. *J Okla State Med Assoc.* 1942(35):365-370.
- Hassell T. Stimulation and inhibition of fibroblast subpopulations by phenytoin and phenytoin metabolites: pathogenetic role in gingival enlargement. *Pediatr Dent.* 1981;3.
- Hassell TM. Epilepsy and the oral manifestations of phenytoin therapy. *Monogr Oral Sci.* 1981;9:1-205.
- Hassell TM. Evidence for production of an inactive collagenase by fibroblasts from phenytoin-enlarged human gingivae. *J Oral Pathol.* 1982;11(4):310-317.
- Hassell TM. Gingival overgrowth: hereditary considerations. *Compend Suppl.* 1990(14):S511-514.
- Hassell TM, Burtner AP, McNeal D, Smith RG. Oral problems and genetic aspects of individuals with epilepsy. *Periodontol 2000.* 1994;6:68-78.
- Hassell TM, Gilbert GH. Phenytoin sensitivity of fibroblasts as the basis for susceptibility to gingival enlargement. *The American journal of pathology.* 1983;112(2):218-223.
- Hassell TM, Hefti AF. Drug-induced gingival overgrowth: old problem, new problem. *Crit Rev Oral Biol Med.* 1991;2(1):103-137.
- Hassell TM, Page RC. The major metabolite of phenytoin (Dilantin) induces gingival overgrowth in cats. *J Periodontal Res.* 1978;13(3):280-282.
- Hassell TM, Page RC, Lindhe J. Histologic evidence for impaired growth control in diphenylhydantoin gingival overgrowth in man. *Arch Oral Biol.* 1978;23(5):381-384.

- Hassell TM, Page RC, Narayanan AS, Cooper CG. Diphenylhydantoin (dilantin) gingival hyperplasia: drug-induced abnormality of connective tissue. *Proc Natl Acad Sci U S A*. 1976;73(8):2909-2912.
- Hassell TM BJ, Cuchens M, Douglas R. Fluorescence activated vital cell sorting of human fibroblast subpopulations that bind cyclosporine A. *J Dent Res*. 1988;67:273.
- Hefti AF, Eshenaur AE, Hassell TM, Stone C. Gingival overgrowth in cyclosporine A treated multiple sclerosis patients. *J Periodontol*. 1994;65(8):744-749.
- Heijl L, Sundin Y. Nitrendipine-induced gingival overgrowth in dogs. *J Periodontol*. 1989;60(2):104-112.
- Hernandez G, Serrano C, Porras L, Lopez-Pintor R, Rubio L, Yanes J. Strawberry-like gingival tumor as the first clinical sign of Wegener's granulomatosis. *J Periodontol*. 2008;79(7):1297-1303.
- Hirschfeld I. Hypertrophic Gingivitis—Its Clinical Aspect**Read before the Section on Periodontia at the Seventy-Third Annual Session of the American Dental Association, Memphis, Tenn., Oct. 21, 1931. *The Journal of the American Dental Association* (1922). 1932;19(5):799-816.
- Ingle JI, Howard WL, Zwick HH. Effects of antihistaminic therapy on diphenylhydantoin sodium (Dilantin) gingival hyperplasia. *The Journal of the American Dental Association*. 1959;58(3):65-71.
- Ingles E, Rossmann JA, Caffesse RG. New clinical index for drug-induced gingival overgrowth. *Quintessence Int*. 1999;30(7):467-473.
- Ishida H, Kondoh T, Kataoka M, Nishikawa S, Nakagawa T, Morisaki I, Kido J, Oka T, Nagata T. Factors influencing nifedipine-induced gingival overgrowth in rats. *J Periodontol*. 1995;66(5):345-350.
- Jacobs D BJ, Cuchens M, Hassell TM. The effect of cyclosporine metabolite OL-17 on gingival fibroblast subpopulations. *J Dent Res*. 1990;69:221.

- Johnson BD, Narayanan AS, Pieters HP, Page RC. Effect of cell donor age on the synthetic properties of fibroblasts obtained from phenytoin-induced gingival hyperplasia. *J Periodontal Res.* 1990;25(2):74-80.
- Jorgenson RJ, Cocker ME. Variation in the Inheritance and Expression of Gingival Fibromatosis. *J Periodontol.* 1974;45(7):472-477.
- Kapur RN, Girgis S, Little TM, Masotti RE. Diphenylhydantoin-induced gingival hyperplasia: its relationship to dose and serum level. *Dev Med Child Neurol.* 1973;15(4):483-487.
- Kaur S, Behl M, Vandana. Clinical assessment of gingival overgrowth in patients treated with anti-hypertensive drugs: A hospital based study. *Journal of the Indian Dental Association.* 2018.
- Kilpinen E, Raeste AM, Collan Y. Hereditary gingival hyperplasia and physical maturation. *Scand J Dent Res.* 1978;86(2):118-123.
- Kimball RF. A Delayed Change of Phenotype following a Change of Genotype in *Paramecium Aurelia*. *Genetics.* 1939;24(1):49-58.
- King GN, Fullinaw R, Higgins TJ, Walker RG, Francis DM, Wiesenfeld D. Gingival hyperplasia in renal allograft recipients receiving cyclosporin-A and calcium antagonists. *J Clin Periodontol.* 1993;20(4):286-293.
- Kitamura K, Morisaki I, Adachi C, Kato K, Mihara J, Sobue S, Hamada S. Gingival overgrowth induced by cyclosporin A in rats. *Arch Oral Biol.* 1990;35(6):483-486.
- Klar LA. Gingival hyperplasia during dilantin-therapy; a survey of 312 patients. *J Public Health Dent.* 1973;33(3):180-185.
- Kornman KS, Loesche WJ. The subgingival microbial flora during pregnancy. *J Periodontal Res.* 1980;15(2):111-122.
- Krolls SO, Hoffman S. Squamous cell carcinoma of the oral soft tissues: a statistical analysis of 14,253 cases by age, sex, and race of patients. *J Am Dent Assoc.* 1976;92(3):571-574.

Lainson PA. Gingival overgrowth in a patient treated with nifedipine (Procardia). *Periodontal Case Rep.* 1986;8(2):64-66.

Lareau DE, Hinrichs JE, Kotsakis GA. Enhancing Root Eminence and Papilla Contour Using Single, Contoured, Subepithelial Connective Tissue Autografts for Recession Coverage. *Int J Periodontics Restorative Dent.* 2017;37(5):751-757.

Lederman D, Lumerman H, Reuben S, Freedman PD. Gingival hyperplasia associated with nifedipine therapy. Report of a case. *Oral Surg Oral Med Oral Pathol.* 1984;57(6):620-622.

Leppik IE. Antiepileptic medications. *Compend Suppl.* 1990(14):S490-496.

Li X, Luan Q, Wang X, Sha Y, He L, Cao C, Jin L. Nifedipine intake increases the risk for periodontal destruction in subjects with type 2 diabetes mellitus. *J Periodontol.* 2008;79(11):2054-2059.

Livingston S. The physician's role in guiding the epileptic child and his parents. *Am J Dis Child.* 1970;119(2):99-102.

Livingston S, Livingston HL. Diphenylhydantoin gingival hyperplasia. *Am J Dis Child.* 1969;117(3):265-270.

Lucas RM, Howell LP, Wall BA. Nifedipine-induced gingival hyperplasia. A histochemical and ultrastructural study. *J Periodontol.* 1985;56(4):211-215.

Maier AW, Orban B. Gingivitis in pregnancy. *Oral Surg Oral Med Oral Pathol.* 1949;2(3):334-373.

Mariani G, Calastrini C, Carinci F, Marzola R, Calura G. Ultrastructural features of cyclosporine A-induced gingival hyperplasia. *J Periodontol.* 1993;64(11):1092-1097.

McGaw T, Lam S, Coates J. Cyclosporin-induced gingival overgrowth: correlation with dental plaque scores, gingivitis scores, and cyclosporin levels in serum and saliva. *Oral Surg Oral Med Oral Pathol.* 1987;64(3):293-297.

Merritt H, Putnam TJ. Sodium diphenyl hydantoinate in the treatment of convulsive disorders. *Journal of the American Medical Association.* 1938;111(12):1068-1073.

- Mihatsch MJ, Kyo M, Morozumi K, Yamaguchi Y, Nickeleit V, Ryffel B. The side-effects of ciclosporine-A and tacrolimus. *Clin Nephrol.* 1998;49(6):356-363.
- Miller CS, Damm DD. Incidence of verapamil-induced gingival hyperplasia in a dental population. *J Periodontol.* 1992;63(5):453-456.
- Miller PD, Jr. Periodontal plastic surgery. *Curr Opin Periodontol.* 1993:136-143.
- Miranda J, Brunet L, Roset P, Farre M, Mendieta C. Reliability of two measurement indices for gingival enlargement. *J Periodontal Res.* 2012;47(6):776-782.
- Mohan RP, Rastogi K, Bhushan R, Verma S. Phenytoin-induced gingival enlargement: a dental awakening for patients with epilepsy. *BMJ Case Rep.* 2013;2013.
- Mombelli A, Lang NP, Burgin WB, Gusberti FA. Microbial changes associated with the development of puberty gingivitis. *J Periodontal Res.* 1990;25(6):331-338.
- Nakagawa S, Fujii H, Machida Y, Okuda K. A longitudinal study from prepuberty to puberty of gingivitis. Correlation between the occurrence of *Prevotella intermedia* and sex hormones. *J Clin Periodontol.* 1994;21(10):658-665.
- Narayanan AS, Meyers DF, Page RC. Regulation of collagen production in fibroblasts cultured from normal and phenytoin-induced hyperplastic human gingiva. *J Periodontal Res.* 1988;23(2):118-121.
- Nery EB, Edson RG, Lee KK, Pruthi VK, Watson J. Prevalence of nifedipine-induced gingival hyperplasia. *J Periodontol.* 1995;66(7):572-578.
- Nishikawa S, Tada H, Hamasaki A, Kasahara S, Kido J, Nagata T, Ishida H, Wakano Y. Nifedipine-induced gingival hyperplasia: a clinical and in vitro study. *J Periodontol.* 1991;62(1):30-35.
- Nuki K, Cooper SH. The role of inflammation in the pathogenesis of gingival enlargement during the administration of diphenylhydantoin sodium in cats. *J Periodontal Res.* 1972;7(2):102-110.
- Omori K, Hanayama Y, Naruishi K, Akiyama K, Maeda H, Otsuka F, Takashiba S. Gingival overgrowth caused by vitamin C deficiency associated with metabolic

syndrome and severe periodontal infection: a case report. *Clinical Case Reports*. 2014;2(6):286-295.

O'Valle F, Mesa F, Aneiros J, Gomez-Morales M, Lucena MA, Ramirez C, Revelles F, Moreno E, Navarro N, Caballero T, et al. Gingival overgrowth induced by nifedipine and cyclosporin A. Clinical and morphometric study with image analysis. *J Clin Periodontol*. 1995;22(8):591-597.

Pagliarini A, Stabellini G, Carinci F, Calura G, Tognon M, Evangelisti R. Heterogeneity of fibroblasts derived from human free and attached gingiva. Glycosaminoglycan synthesis and effects of phenytoin (PHT) treatment. *J Oral Pathol Med*. 1995;24(2):72-77.

Paixao CG, Sekiguchi RT, Saraiva L, Pannuti CM, Silva HT, Medina-Pestana J, Romito GA. Gingival overgrowth among patients medicated with cyclosporin A and tacrolimus undergoing renal transplantation: a prospective study. *J Periodontol*. 2011;82(2):251-258.

Payne AG, Solomons YF, Tawse-Smith A, Lownie JF. Inter-abutment and peri-abutment mucosal enlargement with mandibular implant overdentures. *Clin Oral Implants Res*. 2001;12(2):179-187.

Penarrocha-Diago M, Bagan-Sebastian JV, Vera-Sempere F. Diphenylhydantoin-induced gingival overgrowth in man: a clinico-pathological study. *J Periodontol*. 1990;61(9):571-574.

Pernu HE, Pernu LM, Huttunen KR, Nieminen PA, Knuutila ML. Gingival overgrowth among renal transplant recipients related to immunosuppressive medication and possible local background factors. *J Periodontol*. 1992;63(6):548-553.

Pihlstrom BL. Prevention and treatment of Dilantin-associated gingival enlargement. *Compend Suppl*. 1990(14):S506-510.

Prasad VN, Chawla HS, Goyal A, Gauba K, Singhi P. Incidence of phenytoin induced gingival overgrowth in epileptic children: a six month evaluation. *J Indian Soc Pedod Prev Dent*. 2002;20(2):73-80.

- Raber-Durlacher JE, van Steenberghe TJ, Van der Velden U, de Graaff J, Abraham-Inpijn L. Experimental gingivitis during pregnancy and post-partum: clinical, endocrinological, and microbiological aspects. *J Clin Periodontol.* 1994;21(8):549-558.
- Raeste AM, Collan Y, Kilpinen E. Hereditary fibrous hyperplasia of the gingiva with varying penetrance and expressivity. *Scand J Dent Res.* 1978;86(5):357-365.
- Rateitschak-Pluss EM, Hefti A, Lortscher R, Thiel G. Initial observation that cyclosporin-A induces gingival enlargement in man. *J Clin Periodontol.* 1983;10(3):237-246.
- Rateitschak-Pluss EM, Hefti A, Rateitschak KH. [Gingival hyperplasia from cyclosporin A medication]. *SSO Schweiz Monatsschr Zahnheilkd.* 1983;93(1):57-65.
- Rees TD. Drugs and oral disorders. *Periodontol 2000.* 1998;18:21-36.
- Robinson I. Evaluation of continued therapy with phenytoin sodium. *Am J Psychiatry.* 1942;99(2).
- Romito GA, Pustiglioni FE, Saraiva L, Pustiglioni AN, Lotufo RF, Stolf NA. Relationship of subgingival and salivary microbiota to gingival overgrowth in heart transplant patients following cyclosporin A therapy. *J Periodontol.* 2004;75(7):918-924.
- Rossmann JA, Ingles E, Brown RS. Multimodal treatment of drug-induced gingival hyperplasia in a kidney transplant patient. *Compendium.* 1994;15(10):1266, 1268-1270, 1272-1264; quiz 1276.
- Rostock MH, Fry HR, Turner JE. Severe gingival overgrowth associated with cyclosporine therapy. *J Periodontol.* 1986;57(5):294-299.
- Royer JE, Hendrickson DA, Scharpf HO. Phenytoin-induced hyperplasia of the pre-eruptive stage. Report of a case. *Oral Surg Oral Med Oral Pathol.* 1983;56(4):365-367.
- Russell BG, Bay LM. Oral use of chlorhexidine gluconate toothpaste in epileptic children. *Scand J Dent Res.* 1978;86(1):52-57.

- Schulz A, Lange DE, Hassell TM, Stone CE, Lison AE. [Cyclosporine-induced gingival hyperplasia in renal transplant patients]. *Dtsch Zahnarztl Z.* 1990;45(7):414-416.
- Seibel W. YN, Hassell T., Lesko L. J., Shen S. Y. Gingival enlargement in Beagles undergoing daily cyclosporine therapy. *J Dent Res.* 1987;66:235.
- Seymour RA. Calcium channel blockers and gingival overgrowth. *Br Dent J.* 1991;170(10):376-379.
- Seymour RA, Heasman PA. Drugs and the periodontium. *J Clin Periodontol.* 1988;15(1):1-16.
- Seymour RA, Jacobs DJ. Cyclosporin and the gingival tissues. *J Clin Periodontol.* 1992;19(1):1-11.
- Seymour RA, Smith DG. The effect of a plaque control programme on the incidence and severity of cyclosporin-induced gingival changes. *J Clin Periodontol.* 1991;18(2):107-110.
- Seymour RA, Smith DG, Rogers SR. The comparative effects of azathioprine and cyclosporin on some gingival health parameters of renal transplant patients. A longitudinal study. *J Clin Periodontol.* 1987;14(10):610-613.
- Seymour RA, Smith DG, Turnbull DN. The effects of phenytoin and sodium valproate on the periodontal health of adult epileptic patients. *J Clin Periodontol.* 1985;12(6):413-419.
- Seymour RA, Thomason JM, Ellis JS. The pathogenesis of drug-induced gingival overgrowth. *J Clin Periodontol.* 1996;23(3 Pt 1):165-175.
- Shafer WG. Effect of dilantin sodium on growth of human fibroblast-like cell cultures. *Proc Soc Exp Biol Med.* 1960;104:198-201.
- Shafer WG. Effect of dilantin sodium analogues on cell proliferation in tissue culture. *Proc Soc Exp Biol Med.* 1961;106:205-207.
- Shafer WG. Effect of dilantin sodium on various cell lines in tissue culture. *Proc Soc Exp Biol Med.* 1961;108:694-696.

- Shibley O CS, Adnerson T, Bartz N, Mather M, Farber R. The role of 0.12% chlorhexidine gluconate in drug-induced gingival hyperplasia. *J Dent Res.* 1994;73:356.
- Slavin J, Taylor J. Cyclosporin, nifedipine, and gingival hyperplasia. *Lancet.* 1987;2(8561):739.
- Somacarrera ML, Hernandez G, Acero J, Moskow BS. Factors related to the incidence and severity of cyclosporin-induced gingival overgrowth in transplant patients. A longitudinal study. *J Periodontol.* 1994;65(7):671-675.
- Spencer CM, Goa KL, Gillis JC. Tacrolimus. An update of its pharmacology and clinical efficacy in the management of organ transplantation. *Drugs.* 1997;54(6):925-975.
- Steele RM, Schuna AA, Schreiber RT. Calcium antagonist-induced gingival hyperplasia. *Ann Intern Med.* 1994;120(8):663-664.
- Stinnett E, Rodu B, Grizzle WE. New developments in understanding phenytoin-induced gingival hyperplasia. *J Am Dent Assoc.* 1987;114(6):814-816.
- Taicher S, Mazar A, Hirshberg A, Dayan D. Metastatic chondrosarcoma of the gingiva mimicking a reactive exophytic lesion: a case report. *J Periodontol.* 1991;62(3):223-226.
- Thomas D, Rapley J, Strathman R, Parker R. Tuberos sclerosi with gingival overgrowth. *J Periodontol.* 1992;63(8):713-717.
- Thomason JM, Seymour RA, Ellis JS, Kelly PJ, Parry G, Dark J, Idle JR. Iatrogenic gingival overgrowth in cardiac transplantation. *J Periodontol.* 1995;66(8):742-746.
- Thomason JM, Seymour RA, Ellis JS, Kelly PJ, Parry G, Dark J, Wilkinson R, Ilde JR. Determinants of gingival overgrowth severity in organ transplant patients. An examination of the role of HLA phenotype. *J Clin Periodontol.* 1996;23(7):628-634.
- Thomason JM, Seymour RA, Rawlins MD. Incidence and severity of phenytoin-induced gingival overgrowth in epileptic patients in general medical practice. *Community Dent Oral Epidemiol.* 1992;20(5):288-291.

Thomason JM, Seymour RA, Rice N. The prevalence and severity of cyclosporin and nifedipine-induced gingival overgrowth. *J Clin Periodontol.* 1993;20(1):37-40.

Tyldesley WR, Rotter E. Gingival hyperplasia induced by cyclosporin-A. *Br Dent J.* 1984;157(9):305-309.

van der Wall EE, Tuinzing DB, Hes J. Gingival hyperplasia induced by nifedipine, an arterial vasodilating drug. *Oral Surg Oral Med Oral Pathol.* 1985;60(1):38-40.

Vernillo AT, Schwartz NB. The effects of phenytoin (5,5-diphenylhydantoin) on human gingival fibroblasts in culture. *J Periodontal Res.* 1987;22(4):307-312.

Vijayasingham SM, Dykes PJ, Marks R. Phenytoin has little effect on in-vitro models of wound healing. *Br J Dermatol.* 1991;125(2):136-139.

Walker CR, Jr., Tomich CE, Hutton CE. Treatment of phenytoin-induced gingival hyperplasia by electrosurgery. *J Oral Surg.* 1980;38(4):306-311.

Westbrook P, Bednarczyk EM, Carlson M, Sheehan H, Bissada NF. Regression of nifedipine-induced gingival hyperplasia following switch to a same class calcium channel blocker, isradipine. *J Periodontol.* 1997;68(7):645-650.

Westphal P. [Salivary secretion and gingival hyperplasia in diphenyl hydantoin-treated guinea pigs]. *Sven Tandlak Tidskr.* 1969;62(8):505-508.

White DJ, Plumb AM, Pawelec G, Brons G. Cyclosporin A: an immunosuppressive agent preferentially active against proliferating T cells. *Transplantation.* 1979;27(1):55-58.

Wojcicki CJ, Harper DS, Robinson PJ. Differences in periodontal disease-associated microorganisms of subgingival plaque in prepubertal, pubertal and postpubertal children. *J Periodontol.* 1987;58(4):219-223.

Wynn RL. Calcium channel blockers and gingival hyperplasia. *Gen Dent.* 1991;39(4):240-243.

Wysocki GP, Gretzinger HA, Laupacis A, Ulan RA, Stiller CR. Fibrous hyperplasia of the gingiva: a side effect of cyclosporin A therapy. *Oral Surg Oral Med Oral Pathol.* 1983;55(3):274-278.

Zackin SJ, Weisberger D. Hereditary gingival fibromatosis. Report of a family. *Oral Surg Oral Med Oral Pathol.* 1961;14:828-836.

Ziskin DE BS, Stout AP. The gingivae during pregnancy. *Surg Gynecol Obstet.* 1933;57(719).

10. ENCLOSURES

En 1. Ethical Committee Descision Form



T.C.
MARMARA ÜNİVERSİTESİ
Diş Hekimliği Fakültesi
Klinik Araştırmalar Etik Kurulu

Projenin Adı: Evaluation of index systems measuring gingival overgrowth

Proje yürütücüsü: Prof.Dr.Leyla Kuru
Projedeki Araştırmacılar:Dr.Ahmad Safa Alkateb, Dr.Hafize Öztürk Özener
Onay tarihi ve sayısı:06.06.2017, 2017-113

Sayın Prof.Dr.Leyla Kuru

2017-120 Protokol nolu "Evaluation of index systems measuring gingival overgrowth" isimli in vitro çalışmamız Marmara Üniversitesi Klinik araştırmalar Etik kurulu tarafından incelenmiş ve etik yönden uygunluğuna karar verilmiştir.

M.Ü.Diş Hekimliği Fakültesi
Klinik Araştırmalar Etik Kurulu Başkanı

Prof.Dr.Nimet Gençoğlu

Adı Soyadı

İmza

Prof. Dr. Nimet Gençoğlu

Prof. Dr. İlknur Tanboğa

Prof. Dr. Ali Recai Menteş

Prof. Dr. Yaşar Özcan

Prof. Dr. Abu Acar

Prof. Dr. Zühre Hale Cımilli

Doç. Dr. Buket Evren

Prof. Dr. Şebnem Erçalık Yalçınkaya

Prof. Dr. Filiz Onat

Dr. Zerrin Kurşun

Doç. Dr. Tolga Güven

Doç. Dr. Afife Binnaz Hazar Yoruç

Avukat Burçak Çopuroğlu

Gürol Pekel (sivil üye)



Marmara Üniversitesi
Nispetiye Kampüsü Diş
Hekimliği Fakültesi 34365
Sislihanlı / İZMİR

0 (212) 246 52 47 (Faks)
0 (212) 231 91 20

dişhekimligi@marmara.edu.tr
http://dental.marmara.edu.tr

Ayrıntılı bilgi için:

190YALDI Ünitesi

BİLGİLENDİRİLMİŞ ONAM FORMU

Dişeti büyümesi indeks metodlarının karşılaştırılması

Dişeti büyümesi nedir?

Dişeti büyümesi; enflamasyon, neoplastik koşullar, sistemik hastalıklar ve ilaçlar gibi birçok faktörle ilişkili olan dişetindeki hacimsel bir artıştır.

Dişeti büyümesinin nedenleri nelerdir?

Dişeti büyümeleri esas olarak dental plağın sebep olduğu enflamasyon sonucu, ilaç kullanımına (siklosporin, antikonvulsanlar, kalsiyum kanal blokerleri, vb), hastanın hormonal durumuna (puberte, hamilelik, vb), bazı sistemik hastalıklara (lösemi, granülomatöz hastalıklar) ve hastanın genetik yatkınlığına (herediter gingival fibromatoz) bağlı olarak ortaya çıkar.

Dişeti büyüme boyutları nasıl saptanır?

Dişeti büyüme boyutları, ya ekartör ve ayna yardımıyla çekilen tüm ağız içi fotoğrafları üzerinden ölçüm yapılarak belirlenir ya da ölçü maddesiyle ağız ölçüsü alınarak oluşturulan alçı model üzerinden ölçüm yapılarak elde edilir.

Çalışmanın Amacı: Bu çalışmanın amacı araştırmacının kendi içinde ve araştırmacılar arasında farklı dişeti büyümesi indekslerinin fotoğraf ve alçı model üzerinde tekrar edilebilirliğinin değerlendirilmesidir.

Çalışmanın Süresi: Çalışmanın süresi 6 aydır.

Yapılacak İşlemler

- Öncelikle ağız içi fotoğrafları alınması,
- Devamında aljinat ölçü maddesi kullanılarak ağızın ölçüsünün alınması ve alçı modellerin elde edilmesi.
- Fotoğraf ve alçı modeller üzerinden gerekli ölçümlerin yapılarak sisteme kaydedilmesi.

Gönüllü Hakları, Sorumlulukları ve Gizlilik

Araştırmada tamamiyle kendi isteğiniz doğrultusunda yer almaktasınız. Eğer isterseniz bu çalışmada yer almayabilirsiniz. Bu çalışmada yer aldığınız süre içinde adınız ve tıbbi kayıtlarınız gizli tutulacaktır. Bununla birlikte kayıtlarınız etik kurula, yoklama yapanlara, araştırmacılara ve Sağlık Bakanlığı'na istek olduğu takdirde verilecektir. Bu olur formunu imzalayarak yukarıda adı geçen kurum ve kişilerin söz konusu çalışma verilerine erişebilmelerini ve bu çalışmayla ilgili daha ileri araştırmalar yapılabileceğini (çalışmadan ayrılısanız dahi) kabul ediyorsunuz. Bu süreçte açığa çıkan bilgiler gizli kalacaktır. Çalışma verileri yurtiçinde ve yurtdışında rapor, yayın veya tebliğ olarak yayınlanabilir, ancak adınız ve kişisel bilgileriniz hiçbir şekilde açıklanmayacak ve çalışmayla ilgili veriler izlenerek size ulaşamayacaktır.

Bu çalışmaya katılarak, çalışmadan ayrılısanız dahi herhangi bir verinin kullanımını sınırlamamayı kabul ediyorsunuz. Kişisel verilerinizin dünyadaki tüm Sağlık Bakanlıklarına aktarılabilceğini biliyor ve kabul ediyorsunuz. İlgili ve koruma yasalarınca tanınan haklarınız etkilenmeyecektir.

Herhangi bir sorunuz olduğunda lütfen bize danışınız.

Prof. Dr. Leyla Kuru **Tel: 0 216 421 16 21 (Dahili:1141)**

Dt. Ahmad Safa Alkateb **Tel: 0 216 421 16 21 (Dahili:1143)**

GÖNÜLLÜ ONAM FORMU

Çalışmanın İsmi: Periodontoloji kliniğine başvuran bireylerde dişeti çekilmesinin klinik olarak incelenmesi.

Yukarıda, gönüllüye araştırmadan önce verilmesi gereken bilgileri içeren metni okudum (veya bu metin bana okundu). Bunlar hakkında bana yazılı veya sözlü açıklamalar yapıldı bu form ile ilgili soru soracak zaman ve fırsatım oldu ve tüm sorularım cevaplandı. Bu formun tümünü ve tanımlanan riskleri okudum. Bu koşullarda söz konusu klinik araştırmaya kendi rızamla, hiç bir baskı ve zorlama olmaksızın katılmayı kabul ediyorum. Tıbbi tarihçemi de içeren, kendim hakkında verdiğim her türlü bilginin doğruluğunu da teyit ediyorum.

Gönüllünün Adı-Soyadı:

İmzası

Tarih:

Adresi/Tel:

Gönüllünün Kişisel Olur Vermeye Yeterli Olmadığı Durumlarda

Veli/Vasi, Gerekirse Yasal Temsilcisinin Adı-Soyadı:

İmzası

Tarih:

Adresi/Tel:

Olur Alma İşlemine Başından Sonuna Kadar Tanıklık Eden

Kuruluş Görevlisinin Adı-Soyadı:

İmzası

Tarih:

Adresi/Tel:

Açıklama Yapan Araştırmacının Adı-Soyadı:

İmzası

Tarih:

En 4. Patient's Card

M.Ü. DIŞ HEKİMLİĞİ FAKÜLTESİ PERİODONTOLOJİ A.D. HASTA KARTI

SEANS BAŞLANGIÇLARI:

Tarih : Tarih : Tarih :
Box İmzası : Box İmzası : Box İmzası :

Tarih : Tarih : İşlendi imzası :
Box İmzası : Box İmzası : (Sekreter)

HASTA BİLGİLERİ:

Adı, Soyadı : Meslek :
Yaş, Cinsiyet : Protokol no :
Tel (Cep) : Gönderen :
Adres :

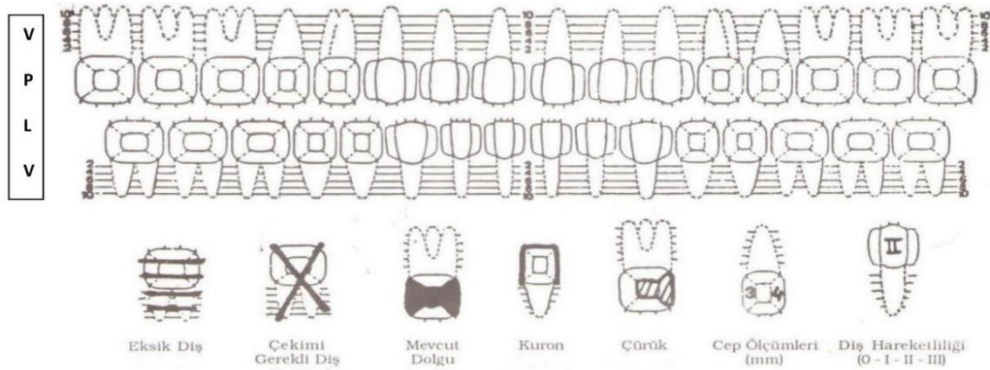
TEDAVİ EDEN HEKİM: Adı, Soyadı : Sınıfı :

DENTAL ANAMNEZ:

Ağrı : Tek taraflı çiğneme (sağ/sol) :
Kanama : Tırnak yeme :
Dişetinde ödem/hiperplazi : Sigara kullanımı / günde :
Dişeti çekilmesi : Daha önce diştaşı temizliği yapıldı mı? :
Ağız kokusu : (ne zaman, nerede)
Dişlerde yer değiştirme / sallantı : Daha önce dişeti tedavisi yapıldı mı? :
Diş sıkma / gıcırdatma : (ne zaman, nerede)
Ağızdan solunum : Diş fırçalama sıklığı / şekli :

SİSTEMİK ANAMNEZ:

Hastanede yattınız mı, neden? : Kalp-damar hastalıkları :
Sarılık : Sindirim sist. hastalıkları :
Tüberküloz / AIDS : Karaciğer hastalığı :
Ateşli romatizma : Böbrek hastalığı :
Diabet : Solunum sist. hastalığı :
Hipertansiyon : Kan hastalığı, anemi :
Hormonal hastalıklar : Kanama zamanı :
Sürekli kullanılan ilaç : Pıhtılaşma zamanı :
Ailedeki genel hastalıklar : Alerji sorunu var mı? :
Ailedeki dişeti hastalıkları : (gıda, penisilin, anestezi madde, ağrı kesici)



HASTANIN ŞİKAYETİ:

TEŞHİS:

En 5. Gingival Overgrowth Measuremet Card

MARMARA ÜNİVERSİTESİ
DİŞHEKİMLİĞİ FAKÜLTESİ
KLİNİK ARAŞTIRMALAR

Patient's code:

(Modified Harris and Ewalt/1998)

17	16	15	14	13	12	11	21	22	23	24	25	26	27
47	46	45	44	43	42	41	31	32	33	34	35	36	37

(Seymour RA/1985)

	13	12	11	21	22	23
V						
P						
L						
V						
	43	42	41	31	32	33

	13	12	11	21	22	23
V						
P						
L						
V						
	43	42	41	31	32	33

(King/1993)

	13	12	11	21	22	23
V						
P						
L						
V						
	43	42	41	31	32	33

	13	12	11	21	22	23
V						
P						
L						
V						
	43	42	41	31	32	33

(Ellis JS, Seymour RA/2001)

	13	12	11	21	22	23
V						
V						
	43	42	41	31	32	33

11. CURRICULUM VITAE

Name	Ahmad Safa	Surname	ALKATEB
Place of Birth	Damascus – Syria	Date of Birth	09.04.1991
Nationality	Syrian / T.C.	Tel	05465914486
E-mail	Safa.alkateb@outlook.com		

Educational Level

	Name of the Institution where he/she was graduated	Graduation year
Postgraduate/Specialization	Marmara University – Faculty of Dentistry	-
Masters	MASTER IN SCIENCE – Department of Periodontology	-
Undergraduate	Aleppo University – Faculty of Dentistry	2014
High school	American High School	2009

Job Experience

Duty	Institution	Duration (Year - Year)
-	-	-

Foreign Languages	Reading comprehension	Speaking*	Writing*
English	Very good	Very good	Very good
Turkish	Good	Moderate	Moderate

Foreign Language Examination Grade#

YDS	ÜDS	IELTS	TOEFL IBT	TOEFL PBT	TOEFL CBT	FCE	CAE	CPE
				77				

	Math	Equally weighted	Non-math
ALES Grade			
(Other) Grade			

Computer Knowledge

Program	Use proficiency
Microsoft office	Very good